

included FEV₁ (forced expiratory volume in 1 second), FEV₁/FVC ratio, PEF (peak expiratory flow) and FEF₂₅₋₇₅ (forced expiratory flow between 25% and 75% of vital capacity) were similar among groups. (Table 2) **Conclusion:** Patients with β -TM may accumulate iron in the interstitial area of the lungs which can lead fibrosis and impaired lung function over time. There are several studies investigated lung dysfunction and its etiology in these patients. Although the results of the studies are varied, the majority of them reported a restrictive pattern of respiratory dysfunction in thalassemia patients. Additionally, some studies showed the presence of mild or moderate obstruction in small airways and decrease in diffusion capacity with the increase of alveolar-capillary membrane thickness at advanced ages. In the present study, we found that patients with β -TM who had high ferritin level showed restrictive type lung function compared to those with low ferritin level. There were no difference among the groups in obstructive parameters (i.e. FEV₁, FEV₁/FVC, FEF₂₅₋₇₅) of PFT. In the literature, studies investigating PFT in patients with high ferritin levels had variable results, impaired or no change, in pulmonary status. In conclusion, loss of respiratory function and impaired tissue oxygenation in patients with β -TM may develop over time due to iron deposition in the interstitial area. PFT assessment of these patients is essential and recommended for the detection of early lung disease. Routine PFT follow in patients with β -TM of high ferritin values is highly important.

<https://doi.org/10.1016/j.htct.2024.04.044>

Nursing, Blood Transfusion, PP 22

UNEARTH WRONG BLOOD TRANSFUSION BY PURSUING MIXED FIELD REACTION

Melek YANASIK¹, Ulku KAFATANCIOGLU¹, Zehra KOCYIGIT CAKIR¹, Burcu DUMAN YILDIRIM¹, Cigdem ATESMEN¹, Neriman YANIK¹, Zeynep OGUZ¹, Tulin TUNC¹, Sevgi KALAYOGLU-BESISIK²

¹ Istanbul University, Istanbul Faculty of Medicine, Blood Center

² Istanbul University, Istanbul Faculty of Medicine, Department of Internal Medicine, Division of Hematology

Case report: ABO-incompatible blood transfusions are potentially life-threatening. The common cause is skipping the final bedside check. Potential intensive and emergent transfusions have the risk of a blood component-patient matching hitch. A 58-year-old bleeding patient with anesthesia received the 4th RBC unit. Pretransfusion tests showed hemolysis in a mixed field. The returned empty bag confirmed the wrong blood group RBC transfusion. The blood bank and hemovigilance intervened; the incident was recorded

<https://doi.org/10.1016/j.htct.2024.04.045>

PP 23

Challenging the Presentation Paradigm in DLBCL: A Case Study of Extraordinary Disease Distribution

Bengisu Ece DUMAN^{1,*}, Candas MUMCU¹, Mujgan COZELI¹, Berra Nur ISCI¹, Emre BAL¹, Meryem SENER², Arzu DEMIR³, Melek ERGIN³, Birol GUVENC²

¹ Cukurova University, Department of Internal Medicine, Adana, Turkey

² Cukurova University, Department of Internal Medicine, Department of Hematology, Adana, Turkey

³ Cukurova University, Department of Pathology, Adana, Turkey

This case study examines a 55-year-old male without previously known comorbidities, who was evaluated due to palpable lymph nodes identified incidentally in the neck, inguinal, and axillary regions. The extensive diagnostic work-up, including advanced imaging, revealed a pattern not commonly associated with diffuse large B-cell lymphoma (DLBCL), including hypermetabolic thickening in the posterior nasopharynx, significant hypermetabolism around the pancreas, and suspicious activity in the spleen and lung. Notably, the involvement extended to both parotid glands and a vast array of lymph nodes, marking an atypical presentation that underscores DLBCL's potential for widespread disease. Biopsies confirmed DLBCL with a non-germinal center phenotype, an aggressive variant with implications for treatment and prognosis. Despite a thorough diagnostic process, the patient elected to forgo the recommended DA-R-EPOCH chemotherapy, highlighting significant ethical and autonomy considerations within the realm of oncological care. This case contributes to the medical literature by illustrating the diagnostic challenges and treatment decision complexities in cases of DLBCL with unusual disease distribution and patient care preferences.

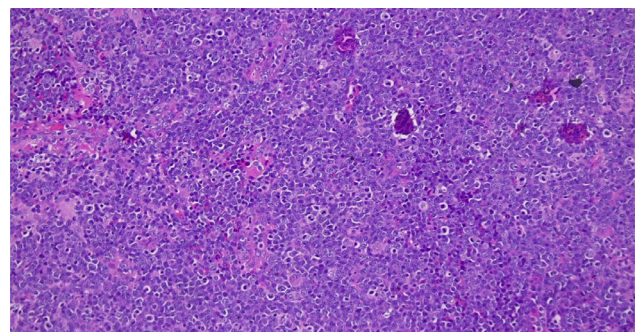


Image 1. Microscopic image of a biopsy taken from the posterior nasopharynx.

<https://doi.org/10.1016/j.htct.2024.04.046>