

malignant melanoma of the breast in long-term local and regional control. **Case report:** A 65-year-old Libyan woman was diagnosed with stage III primary cutaneous malignant melanoma of the breast in 2021. She presented with a progressive painless mass of preexisting nevus, which is located on the skin of the upper inner quadrant of her left breast post-wide local excision without ipsilateral regional lymph node sampling. A month later, a regional ipsilateral axillary LN recurrence occurred. Modified radical mastectomy and axillary LN dissection were done. **Methodology:** subsequently, six cycles of chemotherapy were received, followed by 40 GY in 15 fractions of adjuvant radiotherapy to the left chest wall, ipsilateral axilla, and supraclavicular LNs. In November 2022, lung metastasis was identified, and immunotherapy was advised, Subsequent imaging up to January 2024 indicated no local or regional recurrences and a complete disappearance of lung metastasis. **Results:** The rarity of cutaneous malignant melanomas of the breast has made it difficult to evaluate a life-threatening disease in which local recurrence and regional or distant metastasis may develop after surgical removal of MM, which is common. Wide local excision and prophylactic lymphadenectomy, including radical mastectomy, gave the best long-term local and regional control. Internal mammary node Dissections are not indicated; radiotherapy decreases locoregional failure from 30-50 % to 10–20%. **Conclusion:** Given the notable local, regional recurrence, and distal metastasis rate, local radiotherapy and immune checkpoint inhibitors monotherapy could serve as potent adjuvant treatment in metastatic cutaneous breast malignant melanoma.

<https://doi.org/10.1016/j.htct.2024.04.042>

PP 20

#### EVALUATION OF THE ASSOCIATION OF TUMOR BIOMARKERS WITH CHILDHOOD CANCERS

Şule ÇALIŞKAN KAMIŞ<sup>1</sup>, Metin ÇİL<sup>1</sup>,  
Begül YAĞCI KÜPELİ<sup>1</sup>

<sup>1</sup> Adana City Education and Research Hospital

**Objective:** We aimed to investigate the indications for Carbohydrate antigen 19-9 (CA 19-9), carbohydrate antigen 125 (CA-125), carbohydrate antigen 15-3 (CA15-3) and carcinoembryogenic antigen (CEA) tumor biomarkers, less commonly used in children, and their association with patients diagnosed with childhood cancers. **Methodology:** The study aimed to include patients aged 0-18 who had CA 19-9, CA-125, CA 15-3 and CEA tumor biomarker assessments at Adana City Training and Research Hospital (ACTRH) between 01.11.2022 and 01.11.2023. CA 19-9, CA-125, CA 15-3 and CEA values were recorded from routinely collected serum/blood samples of the patients. The relationship between tumor biomarkers and patients diagnosed with childhood cancers was evaluated. **Results:** The study included 211 patients. Out of 211 patients, 145 (68.7%) were female, and 66 (31.3%) were male. Malignancy was detected in 35 patients (16.6%). There was no statistically

significant relationship observed between CA 15-3, CA 19-9, and CEA positivity and the detection of malignancy. The respective p-values were found to be (p=0.711, p= 0.533, p=0.573). A statistically significant relationship was observed between CA-125 positivity and the detection of malignancy (p=0.002). **Conclusion:** Tumor markers alone are not sufficient for making a definitive diagnosis or determining treatment decisions. However further comprehensive studies are needed for detection of association conventional tumor markers and childhood cancers.

<https://doi.org/10.1016/j.htct.2024.04.043>

PP 21

#### THE EFFECT OF FERRITIN LEVEL ON RESPIRATORY FUNCTIONS IN PATIENTS WITH B-THALASSEMIA MAJOR

Ali ÖZDEMİR<sup>1</sup>, Funda ERKASAR<sup>2</sup>

<sup>1</sup> Mersin City Training and Research Hospital,  
Department of Pediatrics Pediatric Pulmonary  
Section

<sup>2</sup> Mersin City Training and Research Hospital,  
Department of Pediatrics Pediatric Hematology  
Section

**Objective:**  $\beta$ -thalassemia major ( $\beta$ -TM) is an autosomal recessive disorder caused by mutations in the  $\beta$ -globin gene of hemoglobin. The disease is characterized by splenomegaly due to ineffective erythropoiesis, iron accumulation signs in tissues as a result of increased iron absorption, bone expansion due to increased erythropoietic activity, and decreased tissue oxygenation. One of the effected organ can be the lungs due to excessive iron deposition in these patients. The current study aimed to investigate the effect of serum ferritin level, which is known as a marker of iron accumulation in tissues, on pulmonary function tests (PFT) in patients with  $\beta$ -TM. **Methodology:** Patients aged  $\geq 6$  years who were regularly followed in the pediatric hematology section of Mersin City Research and Training Hospital with a diagnosis of  $\beta$ -TM were included. All patients received regular blood transfusion and iron chelation therapy. Study participants underwent PFT prior to blood transfusion in the pediatric pulmonology section. **Results:** A total of 43 patients with  $\beta$ -TM were studied. Included patients were divided into two groups according to the mean annual ferritin level; low ferritin group if below 2000 ml/ng and high ferritin group if above 2000 ml/ng. The low ferritin group was consisted of 19 patients and the high ferritin group was consisted of 24 patients. The characteristics of these two groups are shown in Table 1. There were no statistical significance in age, gender, body mass index, age at diagnosis, mean annual hemoglobin, splenectomy, cardiac involvement and oxygen saturation among both groups, but the number of annual transfusion was significantly higher in the high ferritin group than lower ferritin group. When PFT parameters of both groups were compared, FVC (forced vital capacity) was statistically lower in the high ferritin group compared to the low ferritin group. Other parameters

included FEV<sub>1</sub> (forced expiratory volume in 1 second), FEV<sub>1</sub>/FVC ratio, PEF (peak expiratory flow) and FEF<sub>25-75</sub> (forced expiratory flow between 25% and 75% of vital capacity) were similar among groups. (Table 2) **Conclusion:** Patients with  $\beta$ -TM may accumulate iron in the interstitial area of the lungs which can lead fibrosis and impaired lung function over time. There are several studies investigated lung dysfunction and its etiology in these patients. Although the results of the studies are varied, the majority of them reported a restrictive pattern of respiratory dysfunction in thalassemia patients. Additionally, some studies showed the presence of mild or moderate obstruction in small airways and decrease in diffusion capacity with the increase of alveolar-capillary membrane thickness at advanced ages. In the present study, we found that patients with  $\beta$ -TM who had high ferritin level showed restrictive type lung function compared to those with low ferritin level. There were no difference among the groups in obstructive parameters (i.e. FEV<sub>1</sub>, FEV<sub>1</sub>/FVC, FEF<sub>25-75</sub>) of PFT. In the literature, studies investigating PFT in patients with high ferritin levels had variable results, impaired or no change, in pulmonary status. In conclusion, loss of respiratory function and impaired tissue oxygenation in patients with  $\beta$ -TM may develop over time due to iron deposition in the interstitial area. PFT assessment of these patients is essential and recommended for the detection of early lung disease. Routine PFT follow in patients with  $\beta$ -TM of high ferritin values is highly important.

<https://doi.org/10.1016/j.htct.2024.04.044>

#### Nursing, Blood Transfusion, PP 22

##### UNEARTH WRONG BLOOD TRANSFUSION BY PURSUING MIXED FIELD REACTION

Melek YANASIK<sup>1</sup>, Ulku KAFTANCIOLU<sup>1</sup>, Zehra KOCYIGIT CAKIR<sup>1</sup>, Burcu DUMAN YILDIRIM<sup>1</sup>, Cigdem ATESMEN<sup>1</sup>, Neriman YANIK<sup>1</sup>, Zeynep OGUZ<sup>1</sup>, Tulin TUNC<sup>1</sup>, Sevgi KALAYOGLU-BESISIK<sup>2</sup>

<sup>1</sup> Istanbul University, Istanbul Faculty of Medicine, Blood Center

<sup>2</sup> Istanbul University, Istanbul Faculty of Medicine, Department of Internal Medicine, Division of Hematology

**Case report:** ABO-incompatible blood transfusions are potentially life-threatening. The common cause is skipping the final bedside check. Potential intensive and emergent transfusions have the risk of a blood component-patient matching hitch. A 58-year-old bleeding patient with anesthesia received the 4th RBC unit. Pretransfusion tests showed hemolysis in a mixed field. The returned empty bag confirmed the wrong blood group RBC transfusion. The blood bank and hemovigilance intervened; the incident was recorded

<https://doi.org/10.1016/j.htct.2024.04.045>

#### PP 23

##### Challenging the Presentation Paradigm in DLBCL: A Case Study of Extraordinary Disease Distribution

Bengisu Ece DUMAN<sup>1,\*</sup>, Candas MUMCU<sup>1</sup>, Mujgan COZELI<sup>1</sup>, Berra Nur ISCI<sup>1</sup>, Emre BAL<sup>1</sup>, Meryem SENER<sup>2</sup>, Arzu DEMIR<sup>3</sup>, Melek ERGIN<sup>3</sup>, Birol GUVENC<sup>2</sup>

<sup>1</sup> Cukurova University, Department of Internal Medicine, Adana, Turkey

<sup>2</sup> Cukurova University, Department of Internal Medicine, Department of Hematology, Adana, Turkey

<sup>3</sup> Cukurova University, Department of Pathology, Adana, Turkey

This case study examines a 55-year-old male without previously known comorbidities, who was evaluated due to palpable lymph nodes identified incidentally in the neck, inguinal, and axillary regions. The extensive diagnostic work-up, including advanced imaging, revealed a pattern not commonly associated with diffuse large B-cell lymphoma (DLBCL), including hypermetabolic thickening in the posterior nasopharynx, significant hypermetabolism around the pancreas, and suspicious activity in the spleen and lung. Notably, the involvement extended to both parotid glands and a vast array of lymph nodes, marking an atypical presentation that underscores DLBCL's potential for widespread disease. Biopsies confirmed DLBCL with a non-germinal center phenotype, an aggressive variant with implications for treatment and prognosis. Despite a thorough diagnostic process, the patient elected to forgo the recommended DA-R-EPOCH chemotherapy, highlighting significant ethical and autonomy considerations within the realm of oncological care. This case contributes to the medical literature by illustrating the diagnostic challenges and treatment decision complexities in cases of DLBCL with unusual disease distribution and patient care preferences.

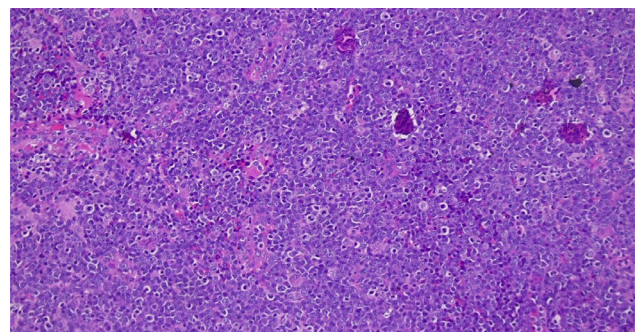


Image 1. Microscopic image of a biopsy taken from the posterior nasopharynx.

<https://doi.org/10.1016/j.htct.2024.04.046>