



Revista Brasileira de Hematologia e Hemoterapia Brazilian Journal of Hematology and Hemotherapy

www.rbhh.org



Case Report

Remission of refractory Crohn's disease after autologous hematopoietic stem cell transplantation



Milton Artur Ruiz*, Roberto Luiz Kaiser Junior, Mikael Alexandre Gouvêa Faria, Luiz Gustavo de Quadros

Associação Portuguesa de Beneficência, São José do Rio Preto, SP, Brazil

ARTICLE INFO

Article history:

Received 28 July 2014

Accepted 27 October 2014

Available online 30 January 2015

Introduction

Crohn's disease (CD) is a regional enteritis that affects the terminal ileum, but has the potential of involving any segment of the gastrointestinal tract of the patient.¹

The etiology of CD is unknown, but several proven risk factors exist such as family history, smoking, oral contraceptives, diet and ethnicity. The combination of risk factors, and aberrant autoimmune response in the intestinal mucosa with endothelial dysfunction lead to digestive tract malfunctioning. Disease manifestations are heterogeneous but most patients present with abdominal pain, diarrhea sometimes with blood, weight loss, fever and perianal lesions. Up to 30% of CD patients have fistulae.

The current treatment is not ideal. Therapy generally involves steroids and anti-tumor necrosis factor alpha (TNF α) blockers but about one-third of patients fail to respond (primary non-responders)² and 10% of patients do not tolerate or are primary non-responders to all drugs used. One-third of responders to anti-TNF α treatment show transient loss

of response (secondary non-responders).³ Severe cases may require partial resection of a segment of bowel, possibly total colectomy with the placement of stoma bags for feces when the disease affects the rectum.^{1,4} Despite new therapeutic strategies, the number of surgeries remains stable.⁵ Many patients evolve well with this approach; however, sometimes the disease persists, becoming refractory and progressive, dramatically affecting the quality of life (QoL) of patients including risk of death.⁶

Thus, new treatment options are needed. Recently, cell therapies with T lymphocytes, tolerogenic dendritic cells and both hematopoietic and mesenchymal stem cells, have started to be researched.⁷

Case report

The case of a 28-year-old female patient is reported with a four-year diagnosis of CD. She had been submitted to the resection of a 40-cm segment of bowel due to stenosis. She was refractory to treatment using corticosteroids, azathioprine,

* Corresponding author at: Rua Catarina Nucci Parise, 760, 15090-470 São José do Rio Preto, SP, Brazil.

E-mail address: milruiz@yahoo.com.br (M.A. Ruiz).

<http://dx.doi.org/10.1016/j.bjhh.2015.01.002>

1516-8484/© 2015 Associação Brasileira de Hematologia, Hemoterapia e Terapia Celular. Published by Elsevier Editora Ltda. All rights reserved.

infliximab and adalimumab. The patient suffered repeated episodes of abdominal pain, mucus bloody diarrhea, weight loss, depression and psychosis.

She had constant, but migratory, joint pain since diagnosis. Moreover, swelling of wrists and skin lesions of all limbs characteristic of psoriatic arthritis were apparent at the first examination.

An anatomopathological study of the antrum and corpus gastricum by endoscopy and colonoscopy showed slight reactive and vascular congestion and an investigation of *Helicobacter pylori* was negative.

Active ileitis and proctitis were observed in the ileocecal valve, right colon, left colon and rectum with extensive areas of ulceration and histologic evidence of inflammatory bowel disease compatible with CD. Additionally, changes in the regenerative architecture were observed as were epithelioid granulomas with multinucleated giant cells but without caseous necrosis (Figure 1).

Autologous hematopoietic stem cell transplantation (HSCT) was indicated. The procedure was only performed after a court order as this procedure is not authorized by the Brazilian healthcare system and after approval by the Hospital Medical Ethics Committee.

Prior to starting the HSCT regimen, the patient was submitted to physical and standard laboratory evaluations.

The Crohn's Disease Activity Index (CDAI) was more than 450 (severely ill) with large ulcerations and involvement of more than 35% of the surface.⁸ Her Montreal classification was A2/L3/B2 with major extraintestinal manifestations including iritis two years previously and polyarticular arthritis. The patient's QoL was determined using the QoL questionnaire – Short Form 36 (QoL SF-36).

The patient was mobilized with cyclophosphamide (60 mg/kg) and granulocyte colony stimulating factor (10 mg/kg) for seven days with 4.59×10^6 CD34⁺ cells/kg being collected from peripheral blood in two leukapheresis sessions (Hemonetics MSC+ USA). The hematopoietic cells were cryopreserved in dimethyl sulfoxide and stored in the vapor phase of liquid nitrogen until transplantation.

The patient was then admitted in the bone marrow transplant unit where she underwent a prophylaxis regimen for parasitic, bacterial, and fungal agents and *Pneumocystis carinii*. Ciprofloxacin was administered for partial bowel decontamination and the patient underwent hyperhydration and mesna prophylaxis to prevent hemorrhagic cystitis. The conditioning regimen consisted of cyclophosphamide (50 mg/day) and rabbit anti-thymocyte globulin (Thymoglobulin, Genzyme – 1.25 mg/kg/day) for four days.

The neutrophils dropped below 0.5×10^9 cells/L after only five days and engraftment occurred on the 10th day after infusion. The patient was discharged on Day +12 and the only toxicity reported was mild mucositis. Transfusion requirements were only two bags of irradiated concentrated red blood cells.

All the symptoms of the disease such as diarrhea and abdominal and joint pain disappeared in the mobilization period before ASCT.

Cytomegalovirus (CMV) reactivation occurred on Day +20, and was treated with ganciclovir (5 mg/kg/day) for 12 days.

Three months after the HSCT, the patient suffered a herpes zoster infection of the back; this improved

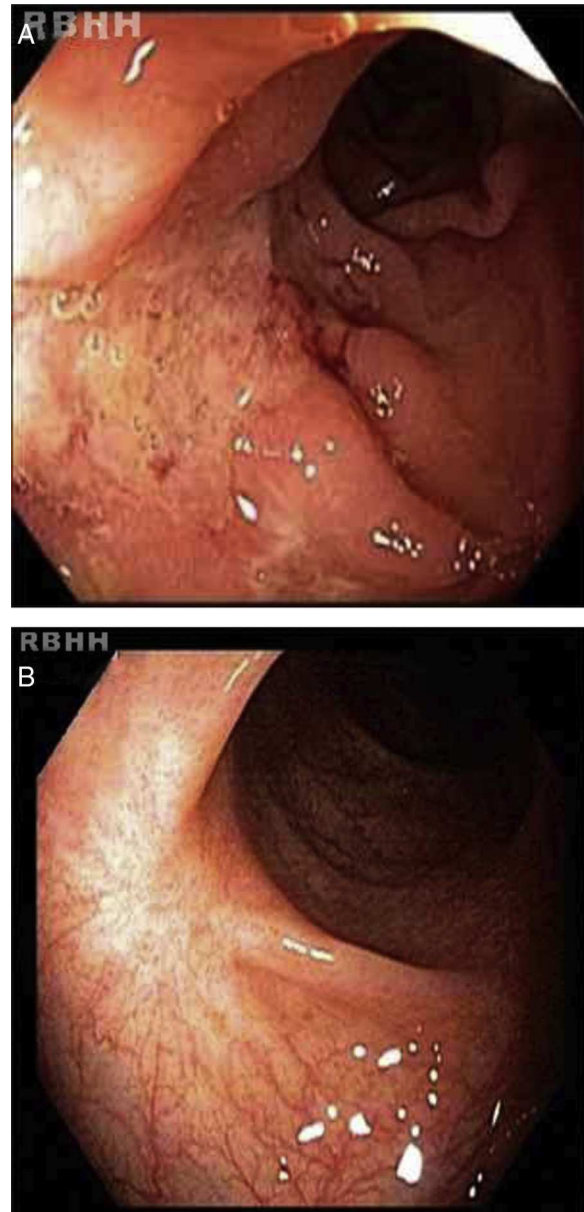


Figure 1 – (A) Serpiginous ulcerations, with fold convergence, intervening ridges of swollen congested mucosa and central fibrinous exudate. (B) White scarring and scar retraction seven months after autologous hematopoietic stem cell transplantation.

within 15 days using specific local and systemic medications.

The results of a second colonoscopy six months after HSCT were normal (Figure 2). One year after the procedure the patient is well, without any symptoms with a CDAI < 150 (clinical remission) and consequent improvements in QoL.

Discussion

Even though high morbidity and mortality rates were associated with autologous HSCT to treat autoimmune diseases,

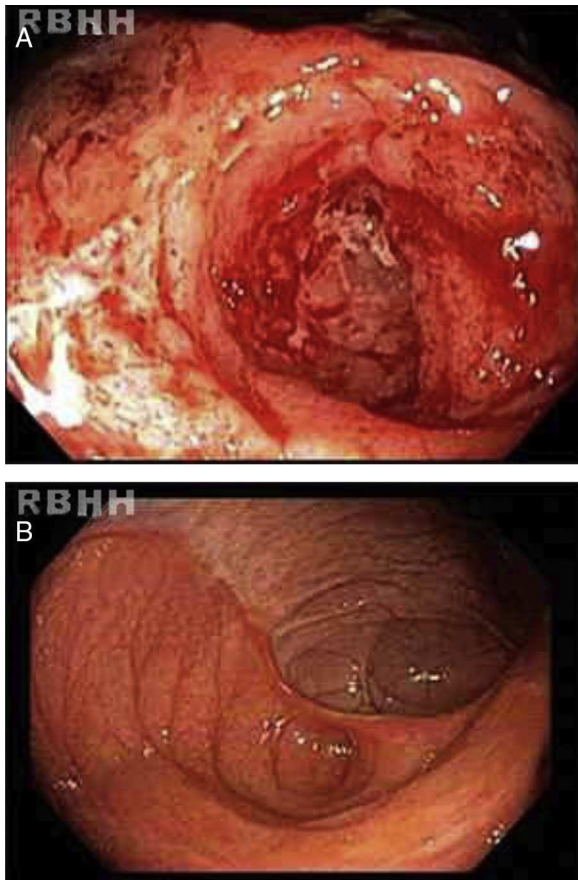


Figure 2 – (A) Ileocolic anastomosis with intense hyperemia, linear ulcers, deformities and spontaneous friability. (B) The same site after autologous hematopoietic stem cell transplantation showing complete mucosal healing.

complication rates have dropped due to experience in this procedure. Similar to several other autoimmune diseases, risk should outweigh the possibility of cure.⁹ Thus, HSCT is a feasible procedure, which, when incorporated to treat autoimmune diseases, can provide good results with clinical remission. The indication of HSCT is based on immune system ablation followed by regulation and regeneration of the T-cell repertoire via immune system resetting.^{10,11}

Reports of HSCT for CD are not as common as some other diseases including multiple sclerosis and systemic sclerosis. Both autologous and allogeneic modalities have been described with consistent clinical and long term remission.¹²⁻¹⁴

The indications of the procedure are not well established. However, HSCT should be considered in specific severe and refractory cases when surgical resection is indicated and in patients with a history of resection. In the current case, the criteria of the European Group for Bone Marrow Transplant (EBMT) were followed as described below.^{15,16}

Autologous HSCT should be indicated:

- In severe cases that do not respond to treatment with immunosuppressive agents and anti-tumor necrosis factors;

- In active or refractory CD that is not controlled by immunosuppressants or biological agents;
- When there is an indication of surgery but with a risk of small bowel syndrome;
- In refractory colonic disease with perianal lesions when colectomy with definitive implantation of the stoma is not accepted by the patient.

In this case the hematologic and gastrointestinal toxicity was minimal. Symptoms such as abdominal pain, profuse bloody diarrhea, joint pain and cutaneous lesions disappeared either during the conditioning regimen or soon after HSCT. The clinical remission described in this case has remained until the present time, one year after the procedure.

Global blockade of immune cells such as T-cells has failed in CD but therapies using mesenchymal, hematopoietic and adipose tissues are promising.¹⁷ The best idea seems to be autologous non-myeloablative HSCT. In the largest series so far, all 24 patients went into remission. Although a large number of patients relapse and require treatment after transplantation, according to Baumgart et al. the percentages of patients in remission, steroid-free or medication-free five years after transplant were at least 70%, 80% and 60%, respectively.¹⁷

HSCT for CD in Brazil is not a procedure authorized by the National Health System or health insurance agencies. HSCT in these situations is restricted to cases enrolled in clinical trials, which do not exist in Brazil as there is no regulation for compassionate treatment. This procedure was possible due to a court order obtained by the patient, because of the severity of the case and compliance to EBMT criteria. There are no other reports of the use of HSCT for CD in Brazil but this procedure seems to be safe and well tolerated by the patient.

Conflicts of interest

The authors declare no conflicts of interest.

REFERENCES

1. Abraham C, Cho JH. Inflammatory bowel disease. *N Engl J Med.* 2009;361(21):2066-78.
2. Colombel JF, Sandborn WJ, Rutgeerts P, Enns R, Hanauer SB, Panaccione R, et al. Adalimumab for maintenance of clinical response and remission in patients with Crohn's disease: the CHARM trial. *Gastroenterology.* 2007;132(1):52-65.
3. Yanai H, Hanauer SB. Assessing response and loss of response to biological therapies in IBD. *Am J Gastroenterol.* 2011;106(4):685-98.
4. Hovde O, Moum BA. Epidemiology and clinical course of Crohn's disease: results from observational studies. *World J Gastroenterol.* 2012;18(15):1723-31.
5. Bernstein CN, Loftus EV Jr, Ng SC, Lakatos PL, Moum B. Hospitalisations and surgery in Crohn's disease. *Gut.* 2012;61(4):622-9.
6. Rabusin M. Haematopoietic stem cell transplantation in severe autoimmune diseases in children. Results and new perspectives. *Bone Marrow Transplant.* 2010;45, 1:S6-7.

7. Martínez-Montiel M del P, Gómez-Gómez GJ, Flores AI. Therapy with stem cells in inflammatory bowel disease. *World J Gastroenterol.* 2014;20(5):1211-27.
8. Vilela EG, Torres HO, Martins FP, Ferrari MA, Andrade MM, Cunha AS. Evaluation of inflammatory activity in Crohn's disease and ulcerative colitis. *World J Gastroenterol.* 2012;18(9):872-81.
9. Sullivan KM, Muraro P, Tyndall A. Hematopoietic cell transplantation for autoimmune disease: updates from Europe and the United States. *Biol Blood Marrow Transplant.* 2010;16(Suppl 1):S48-56.
10. Muraro PA, Douek DC, Packer A, Chung K, Guenaga FJ, Cassiani-Ingoni R, et al. Thymic output generates new and diverse TCR repertoire after autologous stem cell transplantation in multiple sclerosis patients. *J Exp Med.* 2005;201(5):805-16.
11. Alexander T, Thiel A, Rosen O, Massenkeil G, Sattler A, Kohler S, et al. Depletion of autoreactive immunologic memory followed by autologous hematopoietic stem cell transplantation in patients with refractory SLE induces long-term remission through de novo generation of a juvenile and tolerant immune system. *Blood.* 2009;113(1):214-23.
12. Burt RK, Craig RM, Milanetti F, Quigley K, Gozdzia P, Bucha J, et al. Autologous nonmyeloablative hematopoietic stem cell transplantation in patients with severe anti-TNF refractory Crohn disease: long-term follow-up. *Blood.* 2010;116(26):6123-32.
13. Hommes DW, Duijvestein M, Zelinkova Z, Stokkers PC, Ley MH, Stoker J, et al. Long-term follow-up of autologous hematopoietic stem cell transplantation for severe refractory Crohn's disease. *J Crohns Colitis.* 2011;5(6):543-9.
14. Hasselblatt P, Drognitz K, Pothoff K, Bertz H, Kruis W, Schmiidt C, et al. Remission of refractory Crohn's disease by high-dose cyclophosphamide and autologous peripheral blood stem cell transplantation. *Aliment Pharmacol Ther.* 2012;36(8):725-35.
15. Snowden JA, Saccardi RA, Allez RM, Ardizzone S, Arnold R, Cervera R, et al. Hematopoietic stem cell transplantation in severe autoimmune diseases: updated guidelines of the European Group for Blood and Bone Marrow Transplantation. *Bone Marrow Transplant.* 2012;47(6):770-90.
16. Hawkey CJ. Stem cells as treatment in inflammatory bowel disease. *Dig Dis.* 2012;30(Suppl 3):134-9.
17. Baumgart DC, Sandborn WJ. Crohn's disease. *Lancet.* 2012;380(9853):1590-605.