



HEMATOLOGY, TRANSFUSION AND CELL THERAPY

www.htct.com.br


Images in Clinical Hematology

Plasmodium ovale gametocytes in peripheral blood

Angela Lozano-Ochoa ^{a,*}, Verónica Roldán Galiacho ^a,
Leyre Cristina Jiménez Ros ^b, Raquel Pérez Garay ^b, Juan Carlos García-Ruiz ^a

^a Hematology Department, Cruces University Hospital, Biscay, Spain

^b Clinical Laboratory Department, Cruces University Hospital, Biscay, Spain

ARTICLE INFO

Article history:

Received 18 September 2023

Accepted 9 November 2023

Available online xxx

A 54-year-old woman attended the emergency room with history of fever and myalgia. She had arrived from the Central African Republic one month previously. On admission, laboratory data showed: hemoglobin 70 g/L, platelets $41 \times 10^9/L$, leukocytes $0.76 \times 10^9/L$, lactate dehydrogenase 330 U/L [normal: 0–245 U/L], total bilirubin 1.4 mg/dL and C-reactive protein 53.13 mg/L [normal: 0–11 mg/L].

Rapid diagnostic tests for malaria as well as thick film performed upon arrival were negative. A peripheral blood film stained with May-Grünwald and Giemsa showed slightly enlarged red blood cells covered with Schüffner's dots and prominent brown pigment (hemozoin), suggesting infection

by plasmodium at the gametocyte stage. The results obtained by quantitative polymerase chain reaction (qPCR) later on confirmed infection by *Plasmodium ovale*.

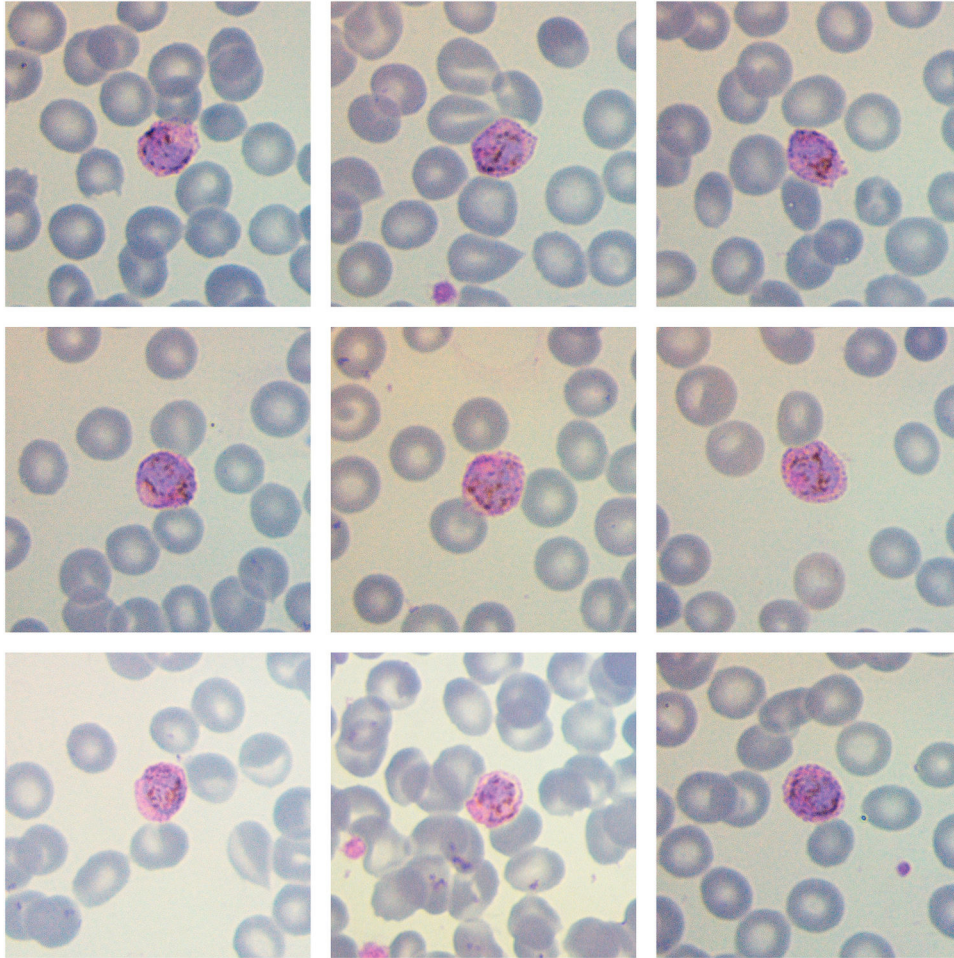
Malaria is a parasite infection caused by *Plasmodium* spp. Traditionally considered the rarest species, in recent years a rise in cases associated with *P. ovale* has been observed. Trophozoites are the most common morphological finding however, after a long incubation period of this species, gametocytes may be found.¹ Stippling is more pronounced and tends to darken the red blood cell. As *P. ovale* exclusively infects reticulocytes, the parasite density is typically low.² *P. ovale* is endemic in western Africa and the

* Corresponding author at: Hematology Department, Cruces University Hospital, Biscay, Spain.

E-mail address: angela.lozanoochoa@osakidetza.eus (A. Lozano-Ochoa).

<https://doi.org/10.1016/j.htct.2023.11.017>

2531-1379/© 2024 Associação Brasileira de Hematologia, Hemoterapia e Terapia Celular. Published by Elsevier España, S.L.U. This is an open access article under the CC BY-NC-ND license (<http://creativecommons.org/licenses/by-nc-nd/4.0/>).



Southwest Pacific. The increase in migration flows underscores the need for an early microscopic identification of this infection, in order to achieve a swift diagnosis and guarantee correct treatment.

Conflicts of interest

I certify that (1) the study submitted has not received any financial support from pharmaceutical industry or other commercial source except those described below, and (2) neither I,

nor any first-degree relative possess any financial interest in the subject approached in the manuscript

REFERENCES

1. Collins WE, Jeffery GM. *Plasmodium ovale*: parasite and disease. Clin Microbiol Rev. 2005;18(3):570–81. <https://doi.org/10.1128/CMR.18.3.570-581.2005>.
2. Wilson ML. Laboratory diagnosis of malaria: conventional and rapid diagnostic methods. Arch Pathol Lab Med. 2013;137(6):805–11. <https://doi.org/10.5858/arpa.2011-0602-RA>.