



Special article

Diagnosis and treatment of systemic mastocytosis in Brazil: Recommendations of a multidisciplinary expert panel



Elvira D. Rodrigues Pereira Velloso ^{a,b,*}, Geórgia A. Padulla ^c,
Ana Maria Mósca de Cerqueira ^d, Adriana Martins de Sousa ^e,
Alex Freire Sandes ^{f,g}, Fabiola Traina ^h, Fernanda Salles Seguro ^a,
Frederico Lisboa Nogueira ^{i,j}, Grazielly de Fátima Pereira ^k,
José Laerte Boechat ^l, Katia Borgia Barbosa Pagnano ^m,
Luan Lima Marchi ^a, Luis Felipe Ensina ^g, Mara Giavina-Bianchi ^c,
Marcelo Vivolo Aun ^{c,n}, Rosana Câmara Agondi ^c,
Fabio Pires de Souza Santos ^{b,o}, Pedro Giavina-Bianchi ^c

^a Service of Hematology, Transfusion and Cell Therapy and Laboratory of Medical Investigation in Pathogenesis and Directed Therapy in Onco-Immuno-Hematology (LIM-31), Hospital das Clínicas da Faculdade de Medicina da Universidade de São Paulo, São Paulo, SP, Brazil

^b Hospital Israelita Albert Einstein, São Paulo, SP, Brazil

^c Clinical Immunology and Allergy Division. Faculdade de Medicina da Universidade de São Paulo, São Paulo, SP, Brazil

^d Hospital Municipal Jesus, Rio de Janeiro, RJ, Brazil

^e Instituto de Pediatria e Puericultura Martagão Gesteira da Universidade Federal do Rio de Janeiro (IPPMG UFRJ), Rio de Janeiro, RJ, Brazil

^f Grupo Fleury, São Paulo, SP, Brazil

^g Universidade Federal de São Paulo (Unifesp), São Paulo, SP, Brazil

^h Faculdade de Medicina de Ribeirão Preto, Universidade de São Paulo (FMRP USP), São Paulo, SP, Brazil

ⁱ Hospital Luxemburgo, Instituto Mário Penna, Belo Horizonte, MG, Brazil

^j Grupo Oncoclínicas, Belo Horizonte, MG, Brazil

^k Hospital das Clínicas da Universidade Federal do Paraná (HC UFPR), Curitiba, PR, Brazil

^l Faculdade de Medicina da Universidade Federal Fluminense (FM UFF), Niterói, RJ, Brazil

^m Hemocentro da Universidade Estadual de Campinas (Unicamp), Campinas, SP, Brazil

ⁿ Faculdade Israelita de Ciências da Saúde Albert Einstein, São Paulo, SP, Brazil

^o A Beneficência Portuguesa de São Paulo, BP, São Paulo, SP, Brazil

Abbreviations: ALP, alkaline phosphatase; ASM, aggressive systemic mastocytosis; BM, bone marrow; BMD, bone mineral density; CM, cutaneous mastocytosis; CT, computed tomography; CTCAE, common terminology criteria for adverse events; DEXA, dual-energy x-ray absorptiometry; ENDA/EAACI, European Network of Drug Allergy/European Academy of Allergy and Clinical Immunology; FACS, fluorescence-activated cell sorting; FDG-PET/CT scan, positron emission computed tomography 2-[fluorine-18]-fluoro-2-deoxy-D-glucose; ISM, indolent systemic mastocytosis; IWG-MRT-ECNM, International Working Group-Myeloproliferative Neoplasms Research and Treatment & European Competence Network on Mastocytosis; MC, mast cells; MCL, mast cell leukaemia; MCS, mast cell sarcoma; MPCM, maculopapular cutaneous mastocytosis; MRI, magnetic resonance imaging; WHO, World Health Organization; PCR, polymerase chain reaction; SM, systemic mastocytosis; SM-ANH, systemic mastocytosis with an associated clonal haematological non-mast cell lineage neoplasm

* Corresponding author at: Service of Hematology, Transfusion and Cell Therapy and Laboratory of Medical Investigation in Pathogenesis and Directed Therapy in Onco-Immuno-Hematology, Hospital das Clínicas da Faculdade de Medicina da Universidade de São Paulo (LIM-31 HCFMUSP), São Paulo, SP CEP 05403-000, Brazil.

E-mail address: elvira.veloso@fm.usp.br (E.D.R.P. Velloso).

<https://doi.org/10.1016/j.htct.2022.04.006>

2531-1379/© 2022 Associação Brasileira de Hematologia, Hemoterapia e Terapia Celular. Published by Elsevier España, S.L.U. This is an open access article under the CC BY-NC-ND license (<http://creativecommons.org/licenses/by-nc-nd/4.0/>).

ARTICLE INFO

Article history:

Received 10 December 2021

Accepted 25 April 2022

Available online 26 May 2022

Keywords:

Mastocytosis

Expert panel

Adults

Children

Diagnosis

Treatment

ABSTRACT

Introduction: Systemic Mastocytosis comprises a group of neoplastic diseases characterized by clonal expansion and infiltration of mast cells into several organs. The diagnosis and treatment of this disease may be challenging for non-specialists. **Objective:** Make suggestions or recommendations in Systemic Mastocytosis based in a panel of Brazilian specialists.

Method and results: An online expert panel with 18 multidisciplinary specialists was convened to propose recommendations on the diagnosis and treatment of Systemic Mastocytosis in Brazil. Recommendations were based on discussions of topics and multiple-choice questions and were graded using the Oxford Centre for Evidence-Based Medicine 2011 Levels of Evidence Chart.

Conclusion: Twenty-two recommendations or suggestions were proposed based on a literature review and graded according to the findings.

© 2022 Associação Brasileira de Hematologia, Hemoterapia e Terapia Celular. Published by Elsevier España, S.L.U. This is an open access article under the CC BY-NC-ND license (<http://creativecommons.org/licenses/by-nc-nd/4.0/>).

Introduction

Mastocytosis is a group of neoplastic disorders characterized by expanding and accumulating clonal and neoplastic mast cells (MCs) in the skin and/or various internal organs, such as the bone marrow, spleen, lymph nodes and gastrointestinal tract.¹ The updated 2016 World Health Organization broadly classifies mastocytosis into cutaneous and systemic forms. In cutaneous mastocytosis (CM), MCs are restricted to the skin, whereas systemic mastocytosis (SM) refers to systemic involvement of several organs by neoplastic MCs.

The SM is more common in adults than children and is a highly heterogeneous disease, both in clinical presentation and prognosis. Life expectancy for patients with SM can range from normal or near-normal to severely reduced, depending on the aggressiveness of the disease.²

Although published international consensuses of experts on the diagnosis and management of patients with SM exist, there have been no guidelines published on managing this disease in Brazil, a low and middle-income (LMIC) country. This study aims to establish expert panel recommendations regarding the diagnosis and management of SM adapted to the reality of the country.

Methods

Eighteen Brazilian experts (including hematologists, immunologists and dermatologists) met online on May 15, 2021, to discuss relevant clinical questions regarding the diagnosis, treatment, and follow-up of patients with SM. Thirty multiple-choice questions, previously defined by 5 of these specialists (area coordinators), were submitted for discussion and voting.

A recommendation was established if at least 75% of the panel agreed with an answer. A suggestion was presented if an agreement of less than 75%, but greater than 49%, was achieved. No recommendations or suggestions were made if there was less than 50% agreement.

The Oxford 2011 Levels of Evidence³ document was used to grade the expert panel recommendations and suggestions.

Results and discussion

The questions used to elaborate these recommendations and the numbers of votes can be found in Supplementary Table 1.

Diagnosis and classification

Mastocytosis is a clonal proliferation of abnormal MCs that accumulate in one or more organs.⁴ The clinical presentation of mastocytosis is heterogeneous, ranging from skin-limited disease (CM) to a more aggressive variant with extra-cutaneous involvement (SM). Criteria for diagnosis were developed by the World Health Organization (WHO) in 2001, with the last update in 2016.⁵ Table 1 shows the current WHO criteria for SM diagnosis and Table 2, the current mastocytosis classification. Figure 1 illustrates several clinical and laboratory features of this disease.

A small study of 24 patients⁶ found that, although all WHO criteria have high specificity (100%), the sensitivity of individual criteria varied from 69% for bone marrow biopsy histopathologic findings to 92% for the presence of an aberrant phenotype in the bone marrow aspirate. These findings led to low negative predictive values in the studied population, ranging from 38% to 75% for the same criteria mentioned above.

The sensitivity of the KIT mutation testing for the SM diagnosis may be enhanced by enriching the sample for abnormal MCs by using laser capture microdissection,⁷ magnetic bead-based, FACS-based cell sorting and other techniques with higher sensitivity.⁸

Suggestion: New or modified diagnostic criteria with higher sensitivity should be included in future revisions of the WHO criteria to diagnose Systemic Mastocytosis (GRADE 3).

It is estimated that most adult patients with mastocytosis have SM,⁹ but that isolated cutaneous disease is more prevalent in pediatric patients.¹⁰ Skin manifestations are observed

Table 1 – World Health Organization (WHO) diagnostic criteria for systemic mastocytosis.

The diagnosis of SM can be made when the major criterion and one minor criterion or at least three minor criteria are present.

Major Criterion

Multifocal, dense infiltrates of mast cells (≥ 15 mast cells in aggregates) detected in sections of bone marrow and/or other extracutaneous organs.

Minor Criteria

- In biopsy sections of bone marrow or other extracutaneous organs, $> 25\%$ of the mast cells in the infiltrate are spindle shaped or have atypical morphology or, of all mast cells in bone marrow aspirate smears, $> 25\%$ are immature or atypical.
- Detection of an activating point mutation at codon 816 of KIT in bone marrow, blood or other extracutaneous organ.
- Mast cells in bone marrow, blood or other extracutaneous organ express CD2 and/or CD25 in addition to normal mast cell markers.
- Serum total tryptase persistently exceeds 20 ng/mL (unless there is an associated clonal myeloid disorder, in which case this parameter is not valid).

“B” findings

- BM biopsy showing $> 30\%$ infiltration by MC (focal, dense aggregates) and/or serum total tryptase level > 200 ng/mL.
- Signs of dysplasia or myeloproliferation, in non-MC lineage (s), but insufficient criteria for definitive diagnosis of a hematopoietic neoplasm (AHNMD), with normal or slightly abnormal blood counts.
- Hepatomegaly without impairment of liver function and/or palpable splenomegaly without hypersplenism and/or lymphadenopathy on palpation or imaging.

“C” findings

- Bone marrow dysfunction manifested by one or more cytopenia(s) (ANC $< 1 \times 10^9/L$, Hb < 10 g/dL or platelets $< 1 \times 10^9/L$), but no obvious non-mast cell hematopoietic malignancy.
- Palpable hepatomegaly with impairment of liver function, ascites and/or portal hypertension.
- Skeletal involvement with large osteolytic lesions and/or pathological fractures.
- Palpable splenomegaly with hypersplenism.
- Malabsorption with weight loss due to gastrointestinal mast cell infiltrates.

Adapted from Ref. 4.

Table 2 – World Health Organization (WHO) classification of mastocytosis.

- Cutaneous Mastocytosis (CM)
 - Urticaria pigmentosa (UP)/Maculopapular cutaneous mastocytosis (MPCM)
 - Diffuse cutaneous mastocytosis
 - Mastocytoma of the skin
- Indolent Systemic Mastocytosis (ISM)
 - Meets criteria for systemic mastocytosis (SM)^a. No “C” findings^a.
 - No evidence of associated clonal hematological non-mast cell lineage disease.
 - Smouldering systemic mastocytosis^b
 - As above (ISM), but with 2 or more “B” findings and no “C” findings^a.
 - Isolated bone marrow mastocytosis^b
 - As above (ISM), with bone marrow involvement, without skin involvement.
- Systemic mastocytosis with an associated clonal hematological non-mast cell lineage disease (SM-AHNMD)
 - Meets criteria for SM and criteria for AHNMD as a distinct entity, per the WHO classification
- Aggressive systemic mastocytosis (ASM)
 - Meets criteria for SM. One or more “C” findings^a. No evidence of mast cell leukaemia.
 - Lymphadenopathic mastocytosis with eosinophilia
- Mast cell leukaemia (MCL)
 - Meets criteria for SM. Bone marrow biopsy shows a diffuse infiltration, usually compact, by atypical, immature mast cells. BM aspirate smears show $\geq 20\%$ mast cells. In typical MCL, mast cells account for $\geq 10\%$ of peripheral blood white cells. Rare variant: aleukaemic MCL.
- Mast cell sarcoma (MCS)
 - Unifocal mast cell tumor. No evidence of SM. Destructive growth pattern. High-grade cytology.
- Extracutaneous mastocytoma
 - Unifocal mast cell tumor. No evidence of SM. No skin lesions. Non-destructive growth pattern. Low-grade cytology.

Adapted from Ref. 4.

^a See definitions of B and C findings in Table 1.

^b Provisional categories.

in approximately 80% of adult patients with SM,¹¹ but a specific population may present with a subvariant form of indolent SM (ISM) solely with bone marrow involvement.⁹ The SM should always be suspected and investigated in adult patients with cutaneous disease.¹²

A bone marrow biopsy is rarely performed for children,⁹ but a recent review suggests that the systemic involvement should be investigated in selected cases.¹³

Cutaneous Mastocytosis (CM) is defined by typical skin lesions of mastocytosis associated with Darier's sign (major criterion) and one or two of the following criteria^{14,15}:

- Increased numbers of mast cells in biopsy sections of lesional skin (approximately 40 mast cells/mm²), and;
- (Activating) KIT mutation in skin lesion. However, it should be noted that at present, only a few laboratories are able to sequence KIT from skin tissue biopsy.

Darier's sign is elicited by stroking a mastocytosis skin lesion approximately 5 times by using moderate pressure with a tongue spatula. Within a few minutes, a wheal-and-flare reaction of the lesion (not or hardly seen in the surrounding skin) will develop.¹⁴

The CM is classified based on macroscopic features and the pattern of the distribution of skin lesions. In contrast to Maculopapular Cutaneous Mastocytosis (MPCM) and diffuse CM, mastocytomas are almost never observed in adults.¹⁶

Patients with SM often also present with cutaneous involvement, which is characterized by erythematous-brown fixed maculopapular lesions. Adults with ISM usually manifest monomorphic maculopapular lesions, whereas children with CM develop polymorphic maculopapular lesions. Maculopapular skin lesions found in patients with ISM and those with CM also occur in patients with advanced SM. It is estimated that approximately 80% of patients with ISM exhibit maculopapular skin lesions, compared to only approximately 50% of patients with advanced SM.¹⁶

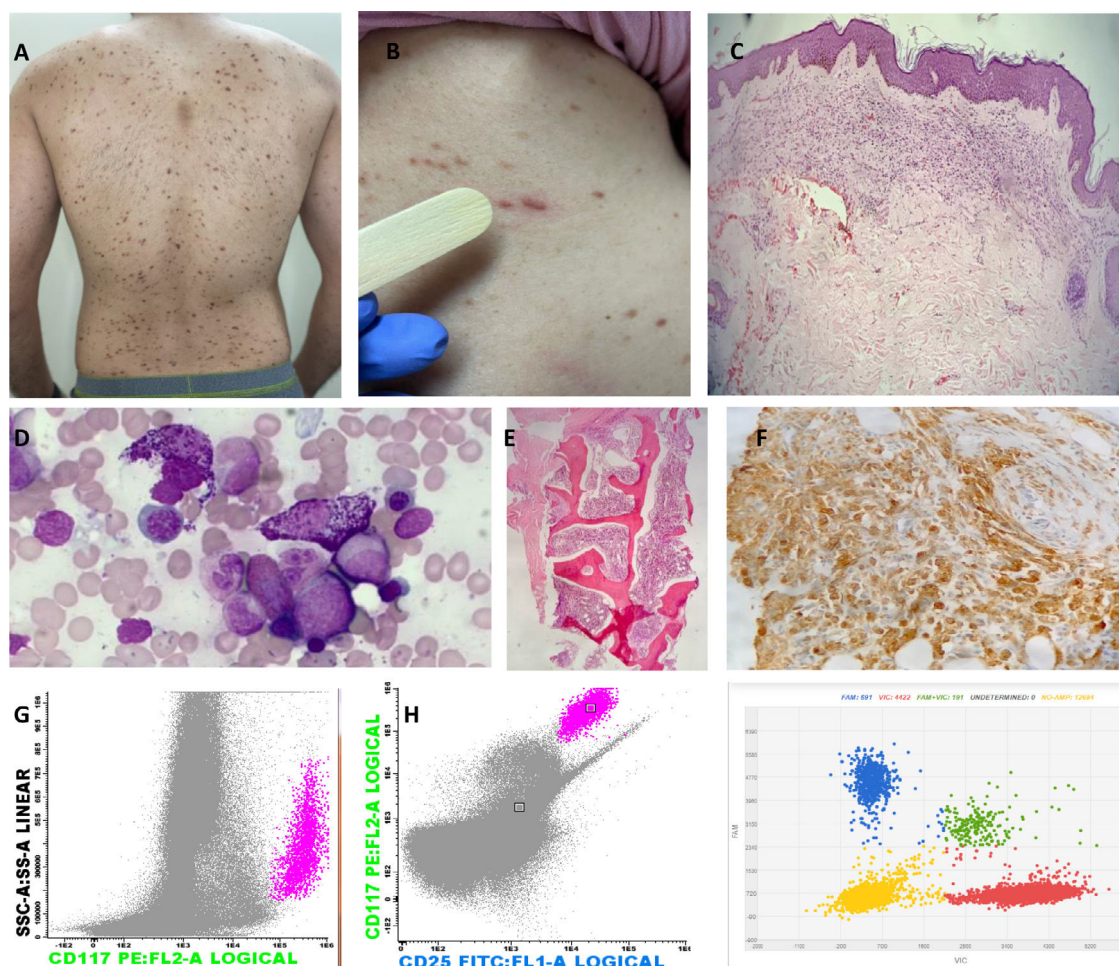


Figure 1 – Images representing major and minor WHO criteria for the diagnosis of SM and cutaneous involvement. (A) Red –brownish maculopapular cutaneous lesions, monomorphic type (formerly known as urticaria pigmentosa) in patients with ISM. (B) Positive Darier's sign – A wheal-and-flare reaction develops upon stroking of a CM lesion with a tongue spatula. (C) The dermal cellular infiltrate consists predominantly of mast cells associated with vascular congestion and mild fibroplasia (H&E, 40x). (D) Bone marrow (BM) aspirate – anomalous hypogranular and spindle-shaped mast cells (Leishman, 200x). (E) BM biopsy – global hypercellularity (95%), extensive infiltration by mast cells. Bone BM trabeculae without significant histological changes (H&E, 200x). (F) Immunohistochemistry of BM shows a large mast cell burden (CD117 immunostaining counterstained with Harris hematoxylin, 400x). (G) Flow cytometry of BM cells shows anomalous CD25+ mast cells (pink dots); mast cells are identified through CD117 positivity and the high internal complexity of the cells, anomalous phenotype CD117+/CD25+. (H) Digital PCR (peripheral blood analysis) for the D816V mutation. Red represents the wild-type codon and blue represents the D816V mutation. Two copies are represented together in green (wild-type and mutated); the yellow color represents the absence of the studied gene.

Recommendation: Cutaneous Mastocytosis should be diagnosed only after the dermatological clinical evaluation, anatomopathological examination and exclusion of Systemic Mastocytosis criteria (GRADE 1).

Tryptase is a serine protease predominantly produced by tissue mast cells and is the most specific marker of MC activation and burden.¹⁶ Elevated serum tryptase can be found in several clinical conditions and diseases.^{16,17}

In SM, a persistently elevated serum tryptase level (> 20 ng/ml) is a minor diagnostic criterion in the WHO diagnostic framework⁵; levels vary widely, but serum tryptase is elevated in the vast majority of SM patients across all WHO subgroups. A significantly greater proportion of Aggressive Systemic Mastocytosis (ASM) and Systemic Mastocytosis with an

Associated Clonal Hematological Non-Mast Cell Lineage Neoplasm (SM-AHN) patients exhibit a markedly more elevated serum tryptase level (> 200 ng/ml) than those with ISM.⁴ Patients with CM, except for cases with extensive skin involvement, typically exhibit normal levels of total tryptase and serum tryptase has been shown to be a sensitive marker for the SM diagnosis.^{18–20}

Serum basal levels of tryptase also correlate with disease progression and response to treatment²¹ and, therefore, should be tested periodically, particularly in advanced cases.

Recommendation: Tryptase level measurements are necessary for the Systemic Mastocytosis diagnosis and follow-up (GRADE 2) at least once a year (GRADE 5).

In patients with SM, the bone marrow is the organ most targeted by MCs. The evaluation of bone marrow, including the bone marrow aspirate, immunophenotyping by flow cytometry and histopathological evaluation of the bone marrow biopsy, can detect infiltration by neoplastic, abnormal MCs and is one of the cornerstones for the diagnosis of SM by the WHO SM criteria.^{4,5} Indeed, according to the 2016 WHO Classification, detection of multifocal dense infiltrates of MCs (≥ 15 mast cells in aggregates) in the bone marrow is a major criterion for the SM diagnosis. The presence of atypical morphology in more than 25% of the MCs, including spindle-shaped MCs, is considered a minor criterion.⁵ Thus, bone marrow evaluation by a unilateral bone marrow biopsy with a histopathological review, preferably by a pathologist with expertise in recognizing MC disorders, is mandatory.^{4,5,22}

Moreover, the immunophenotyping evaluation of the MCs can help detect small infiltrates that are not readily apparent in the morphological evaluation of the marrow biopsy.^{23,24} The immunohistochemical staining for CD117 and tryptase can readily detect the presence of small MC aggregates, but cannot distinguish between normal and neoplastic MCs.²⁵ The expression of the CD25 and/or CD2 can help in the differentiation of normal (negative for these markers) and neoplastic (positive for these markers) MCs²⁵ and the expression of CD25 and CD2 is also considered a minor criterion by the 2016 WHO Classification.² Of the two markers, the CD25 appears to be the most sensitive, being found in most cases of both advanced and indolent SM.²⁶ The CD25 and CD2 can be evaluated by immunohistochemistry in the marrow biopsy and/or by flow cytometry.

Most patients with systemic mastocytosis harbor mutations in the KIT gene, which encodes the stem cell factor receptor CD117, a class III receptor tyrosine kinase expressed by MCs, hematopoietic progenitor cells, germ cells, melanocytes and interstitial cells of Cajal in the gastrointestinal tract.²⁷ The gain-of-function D816V mutation in the KIT gene is detected in most ($> 95\%$) adult patients with SM.²⁸ Other KIT mutations are found in pediatric patients with CM²⁹ and a minority of adult SM patients.⁴ Some of these other KIT mutations and the rare case of SM with wild-type KIT may involve disease that is responsive to the tyrosine kinase inhibitor imatinib.^{30,31}

The D816V KIT mutation allele burden was also found to correlate with disease activity, disease subtype and survival.^{28,32,33} This mutation confers the receptor with a conformational modification, rendering cells resistant to imatinib.³⁴ Some patients with increased MCs and eosinophilia may carry the FIP1L1-PDGFR α fusion gene associated with imatinib sensitivity.³⁵ However, it should be mentioned that, according to the 2016 WHO Classification, such a disease would be classified as the Myeloid/Lymphoid Neoplasm with PDGFR α rearrangement, and not SM.⁵

Analysis of KIT mutations in bone marrow cells is a standard diagnostic procedure for SM. In most patients with SM, particularly those with ISM, the burden of neoplastic MCs in the bone marrow can be very low and this may represent a technical challenge in detecting the mutation, if only conventional detection methods are employed (e.g., Sanger sequencing).³⁶ The sensitivity of the KIT mutation testing for the SM diagnosis may be enhanced by enriching the sample for

neoplastic MCs by laser capture microdissection, magnetic bead-based, FACS-based cell sorting, or using digital/allele-specific PCR techniques with high sensitivity.^{8–37}

Recommendation: The D816V KIT mutations should be investigated in all patients with Systemic Mastocytosis. The FIP1L1-PDGFR α fusion gene needs to be investigated in patients with increased BM mast cells and eosinophilia (GRADE 2).

Imaging studies can determine the degree of mast cell infiltration in specific organs. Magnetic resonance imaging (MRI) is more sensitive than conventional X-rays in detecting bone marrow involvement and a whole-body MRI exam may also contribute to determining the presence of B/C-finding factors, such as the presence of hepatosplenomegaly and ascites.³⁸

The most common bone abnormality in patients with SM is diffuse demineralization, which can be revealed by the bone mineral density (BMD) of the lumbar spine and femur with the dual-energy X-ray absorptiometry (DEXA) technique.³⁸ The Tc99 bone scintigraphy can detect diffuse bone involvement and a greater number of focal lesions, with a higher sensitivity than plain radiography.³⁹

Infiltration of the intestinal tract by MCs can be confirmed by biopsy during colonoscopy, but bowel involvement rarely correlates with symptoms.⁴⁰ Abdominal ultrasonography is the most common initial study in patients with SM to assess abdominal involvement.³⁸ Computed tomography (CT) scans are also used to detect abdominal signs of MC infiltration in the liver, spleen and other abdominal organs.^{38,41} Although the findings in patients with SM are not specific, they may be used to direct further studies for diagnostic confirmation and to estimate the extent of systemic involvement.⁴²

Positron emission tomography/computed tomography with 2-[fluorine-18]-fluoro-2-deoxy-D-glucose (FDG-PET/CT scan) has been shown in a multicenter study⁴³ and in a case series of five SM patients⁴⁴ to have little value in diagnosing or staging most forms of the disease. Higher uptake was detected in patients with SM-AHN, mast cell sarcoma (MCS)⁴³ and in a single case report of an MCL patient with extramedullary involvement.⁴⁵

Recommendation: Doppler abdominal ultrasound should be performed for all patients with Systemic Mastocytosis to evaluate hepatomegaly, portal hypertension and ascites (GRADE 3).

Recommendation: CT scans and MRI should be used to evaluate Systemic Mastocytosis “C” findings. The FDG-PET/CT scans should not be part of the initial assessment of the most common forms of the disease (GRADE 3).

Prognosis

The 2016 WHO classification of Systemic Mastocytosis is the most practical first step in determining prognosis for each case.⁴ A study with 342 patients performed at the Mayo Clinic⁴⁶ validated the prognostic relevance of the WHO classification system; the multivariable analysis showed a significant and independent association of inferior survival with WHO subtype ($p < 0.001$), advanced age ($p < 0.001$), weight loss ($p < 0.01$), anemia ($p < 0.007$), thrombocytopaenia ($p < 0.001$), hypoalbuminemia ($p < 0.001$) and excess BM blasts ($> 5\%$; $p < 0.004$). In a more recent analysis of 580 patients, the Mayo Alliance Prognostic System (MAPS) developed a hybrid clinical-molecular model

that included age > 60 years, WHO-defined advanced SM, thrombocytopenia < $150 \times 10^9/L$, increased serum ALP and anemia (defined as a hemoglobin level below the sex-adjusted normal reference range) or adverse mutations (ASXL1, RUNX1 and NRAS). The survival correlated directly and proportionally with the number of risk factors.⁴⁷

Recommendation: The clinical or hybrid Mayo criteria should be used to determine prognosis (GRADE 4).

Treatment and follow-up

The treatment of SM should be individualized and varies from a watch-and-wait period to the symptom management, supportive measures and cytoreductive therapy for MC debulking in the setting of aggressive, advanced or treatment-refractory disease.⁴ Allogeneic stem cell transplantation is another option for patients with SM-AHN or ASM.^{48,49}

The symptomatic treatment aims to manage symptoms efficiently and minimize their recurrence. The avoidance of triggers and use of prophylactic medication, when risk avoidance is difficult or impossible, are necessary first measures for symptomatic control.⁴⁹ Mastocytosis symptoms can be divided into skin symptoms, mast cell mediator “release” symptoms and symptoms caused by non-cutaneous organ infiltration.⁵⁰

The treatment of mild clinical manifestations is mainly symptomatic and consists of the following: H1-histamine receptor blockers for general symptoms; H2-histamine receptor blockers, mainly for gastrointestinal symptoms, and; leukotriene receptor blockers and mast cell stabilizers.⁴⁹ Glucocorticoids may be useful in treating SM for acute reactions, though long-term adverse effects may limit their use. Cutaneous manifestations may also respond to topical corticosteroids and calcineurin inhibitors.⁵¹ See Table 3 for the treatment of cutaneous symptoms in SM.

Brazzelli et al⁵² published a research report on 20 patients with CM and ISM treated with the PUVA therapy (UVA plus psoralen therapy) and NB-UVB (narrowband UVB), with good results. In general, however, it is a method of limited efficacy and only partial and temporary improvement of skin signs and symptoms can be achieved. The carcinogenic effect of phototherapy and photochemotherapy should also be considered, particularly with long-term or recurrent ultraviolet phototherapy, which is needed to achieve a skin response in CM.

The melanoma incidence seems to be elevated in patients with mastocytosis⁵³ and careful monitoring of premalignant skin lesions should be carried out periodically.⁵⁴

Recommendation: The treatment of cutaneous disease should focus on symptomatic relief and trigger avoidance (GRADE 2).

Recommendation: Antihistamines should be used for the symptomatic treatment (GRADE 2).

Suggestion: Antihistamines may be used for prophylactic treatment, especially in highly symptomatic patients (GRADE 2).

Recommendation: The follow-up in patients with indolent or smouldering Systemic Mastocytosis should include symptomatic management and bone disease measurement (GRADE 3).

Recommendation: A dermatological examination should be performed at least once a year. Emollients, insect

Table 3 – Principles of treatment of cutaneous involvement in systemic mastocytosis.

General measures - ALL PATIENTS

1. Avoidance of Triggers

- Avoid medication that directly activate mast cells, allergens, Hymenoptera stings and other triggers[§]
- Physical stimulus

Avoid sudden changes and extreme temperatures in bath/shower, swimming pool, air conditioning and environment

2. Skin care

- Avoid dryness of skin
- Use skin moisturizer

3. Photoprotection

Regular Medications for Symptomatic Patients

1. Maculopapular skin lesions, itching and flushing

- H1 antihistamines (first and second generation)
- H2 antihistamines

2. Continuous moderate symptoms

- Scheduled non-sedating H1 antihistamines, add sedating H1 antihistamines on demand
- Scheduled or on demand H2 antihistamines (e.g., famotidine)
- Mast cell membrane stabilizers[&]

3. Severe symptoms

- All of the above
- Add anti-leukotrienes (e.g., montelukast)

Alternative treatments

1. Topical

- Corticosteroid cream^{*}
- Topical calcineurin inhibitors⁺
- Sterile gauze with zinc sulphate[#]

2. Systemic treatment

- Corticosteroids^{*}

3. Physical treatment

- Phototherapy – second-line
- Lasers (Dye-lasers/Nd-Yag)

4. Surgery

- Solitary Mastocytoma could be considered for excision as a third line treatment.

[§] Repellents can be used to prevent insect bites but do not protect against Hymenoptera bites

[&] Ketotifen ± oral or cream 1 disodium cromoglycate (the commercial form is only available in manipulation pharmacies at a high cost in Brazil).

^{*} In general, may reduce skin symptoms and lead to cosmetic improvement. Nevertheless, these medicines should be prescribed only for short-term therapy due to numerous skin side effects, including cutaneous atrophy, telangiectasia, hyperpigmentation, hypopigmentation and systemic side effects, such as osteopaenia, or adrenocortical suppression in repeated or extensive application.

⁺ pimecrolimus 1% cream 2 x/day seems to be an alternative therapy with few adverse effects and safety, but with few studies and low level of evidence.

[#] Diffuse forms with life-threatening mast cell-mediated symptoms. Related symptoms, bullae and blistering - treatment may require hospitalization.

repellents, H1 ± H2 antihistamines, sunscreens, ketotifen and cromoglycate^{*} are the basis of treatment (GRADE 4) ^{*} (GRADE 2).

The anaphylaxis is a significant complication in mastocytosis patients. Although the risk of anaphylaxis is less than 10% in children with CM, it is estimated to be 50% in adults with ISM.⁵⁵ Anaphylactic reactions may be elicited by drugs, hymenopteran (bee, wasp and ant) venom, physical factors, such as heat and friction and infection, among other inducers.⁵⁶ The risk of anaphylaxis should be evaluated prior to a medical

Table 4 – Drugs that directly activate mast cells and should be prescribed with caution, only if inevitable.

Opioids
Neuromuscular blocking agents
Quinolones and Vancomycin
Iodinated contrast media
Non-steroid anti-inflammatory drugs (NSAIDs)*
Hermans et al. showed that the risk is not very high. ⁶² Guidance must be personalized and patients taking NSAIDs without having adverse reactions can continue to use them.

procedure to determine the need for premedication, as proposed by Hermans et al.⁵⁷ Risk factors for complications depend on the procedure (use of general anesthesia and major surgery) and patient clinical features (history of anaphylaxis, use of medication, severe skin infiltration, etc.).^{56,57}

The anaphylaxis may be induced by allergic (IgE-mediated) and non-allergic mechanisms (direct mast cell activation).^{58,59} Patients with mastocytosis have a higher prevalence of hymenopteran venom allergy, but not of drug or food allergy, in comparison to the general population.⁶⁰ The Hymenoptera (bees, wasps and ants) acts through both allergic IgE-mediated mechanisms and direct mast cell activation.⁶¹ There is a specific ISM patient phenotype, with no cutaneous involvement and anaphylactic shock, induced by the hymenopteran venom.⁶² Patients with SM and allergies to Hymenoptera should undergo lifelong immunotherapy.

Drugs that directly activate mast cells may induce non-allergic anaphylactic reactions in mastocytosis patients^{63,64} and these drugs should be used with the utmost caution (Table 4). A Spanish study of 501 mastocytosis patients who underwent 726 anesthetic procedures showed that MC mediator-related symptoms and anaphylaxis were present in 2% and 0.4% of adults and 4% and 2% of children, respectively.⁶⁵ Neuromuscular blocking agents and opioids are the main drugs involved in reactions in these situations. An ENDA/EAACI systematic review did not find clear evidence of higher risks with general or local anesthetics, beta-lactam antibiotics and radio-contrast media.⁶⁶

In children with mastocytosis, the percentage of anaphylaxis has been reported to be between 6% and 9%, but adults have a much higher incidence (22% to 49%).⁵⁵ In a study of 120 patients, including children and adults,⁶⁰ major perceived trigger factors for adults were hymenopteran stings (19%), foods (16%) and medications (9%); however, in 26% of the reactions, only a combination of different triggers preceded the anaphylaxis. Trigger factors remained unidentified in 67% of the reactions in children, compared to 13% in adults. Patients with anaphylaxis had higher basal tryptase values (60.2 ± 55 ng/ml, $p < 0.0001$) than those without anaphylaxis (21.2 ± 33 ng/ml). In another study⁶⁷ of adult SM patients, 36 of 84 patients were identified as having had at least one episode of an anaphylactic reaction (43%); 22 patients had single episodes, with the remaining 14 patients having 55 episodes. Reactions without known triggers, that is, idiopathic reactions, were also common in this cohort, totaling 39% (14/36). In contrast, only three patients had a history

of anaphylaxis after ingestion of foods (one case) or drugs (two cases).

Recommendation: The use of prophylaxis before procedures should be individualized, depending on the procedure and the form of the disease (GRADE 1). The premedication before the skin biopsy is usually not necessary. However, the use of premedication to decrease the risk of anaphylaxis before invasive procedures, such as bone marrow biopsy and endoscopy, is recommended.

The self-injectable epinephrine (two doses) should be carried by all patients with SM all the time, even if previous anaphylaxis has not occurred. Both the patient and family members/caregivers should be trained in administering epinephrine.^{60,68–71}

Recommendation: The intramuscular epinephrine should be used as an emergency treatment for anaphylactic reactions (GRADE 5).

Recommendation: Beta-lactam antibiotics and local anesthetics can be safely prescribed for Systemic Mastocytosis patients (GRADE 1).

The authors suggest that patients with a known tolerance to NSAIDs can continue the treatment, whereas a diagnostic workup should be performed for those with a prior reaction to NSAIDs.⁶⁶

Recommendation: The NSAID indications should be individualized for each patient (GRADE 1).

In a survey by the Mastocytosis Society, over half of the mastocytosis patients reported allergic symptoms after ingestion of certain foods and beverages.⁷² On the other hand, Jarkvist et al.⁷³ analyzed complete allergic workups in 187 SM patients and found that the prevalence of food hypersensitivity reactions or food allergies was the same as that in the general population (17.2% and 3.4%, respectively).

Recommendation: Systemic Mastocytosis patients have the same frequency of food allergies as the general population and there is no need for a prior food restriction due to potential allergies (GRADE 2).

Mast cell mediators, mainly interleukin-6, affect the bone metabolism⁷⁴ and the presence of osteoporosis in SM patients varies from 8% to 41%.⁷⁵ Fragility fractures due to osteoporosis are also common, particularly in men⁷⁶ and patients without skin involvement⁷⁷ with ISM. The bone density may be increased with denosumab⁷⁸ or zoledronic acid.⁷⁹ Vitamin D and calcium were included in a bisphosphonate regimen in another study of 23 patients with ISM and osteoporosis, showing increased bone mineral density in all evaluated patients (9/9).⁸⁰ Antiresorptive drugs reduce the incidence of fragility fractures in these patients, though they may still occur in patients with a previous fracture occurrence.⁸¹

Recommendation: Bisphosphonates and vitamin D, plus calcium treatment, are recommended for SM patients with osteopenia/osteoporosis (T score ≤ 2) (GRADE 4). Patients with osteoporosis should be referred to a specialist.

Recommendation: The cytoreductive therapy is indicated in patients with pathological fractures (GRADE 5).

The ASM has a worse prognosis than ISM, presenting with “C” findings (Table 1), organ dysfunctions and, less frequently,

cutaneous disease.⁸² The cytoreductive treatment is indicated for these patients, in whom the need to control the myeloproliferation and reduce damage to target organs outweighs the potential side effects of therapies.⁸³ The choice of the most appropriate therapy should be determined, based on the clinical picture and molecular data (particularly the KIT mutational status and additional high-risk mutations).⁸³

The imatinib, a competitive inhibitor of several tyrosine kinases, including the KIT, has been tested in SM patients, with disappointing results.^{84,85} The imatinib inhibits the growth of cells with the wild-type KIT or V560G KIT, but not cells bearing the D816V KIT mutation. The resistance to imatinib in patients with the KIT D816V mutation may result from a conformational change in the activation loop located at the entrance to the KIT enzymatic pocket. The conformational change interferes with imatinib binding to the receptor, rendering the cells resistant to its effect.⁸⁶ In selected patients with SM and KIT non-D816V mutations, the use of imatinib may lead to good results.^{30,31,87}

Recommendation: The imatinib is a treatment option for patients with recently diagnosed aggressive SM and a negative test for the D816V KIT mutation or in the presence of other mutations known to be sensitive to imatinib (or in situations in which genetic tests are not available) (GRADE 4).

The interferon- α (IFN- α) has been tested in 76 SM patients in 6 different studies from 2002 to 2009 (reviewed by Weis Bjerrum et al.⁸⁸). Complete responses were seen in 7% and 46% responded partially. Adverse reactions are a significant hurdle for long-term use of the IFN- α in the treatment of patients with SM and the dose escalation may be difficult to achieve.⁸⁸

Although MC mediators are involved in several aspects of pregnancy, little is known about the effects of SM in pregnancy and vice versa.⁸⁸ The treatment should be directed towards relieving SM symptoms, while weighing the risks of medications to the fetus. The use of the IFN- α for the treatment of other conditions during pregnancy was not associated with maternal or fetal complications or malformations and its use may be considered for pregnant women who need cytoreductive therapy.⁸⁹

Recommendation: The interferon-alpha should be considered for pregnant patients with advanced systemic mastocytosis (GRADE 4).

The cladribine has been evaluated in two retrospective studies,^{90,91} showing partial responses in 72% and 50% of the patients. One patient in the study of Lim et al.⁹¹ experienced a complete response. Patients with less aggressive disease had a better response rate in the Barete et al. study,⁹⁰ with ISM (89%), SSM (100%) and CM (100%), compared to ASM (43%) and SM-AHNMD (59%) ($p < 0.001$). The main adverse events in both studies were myelosuppression and infection. The cladribine may also be helpful in patients with ISM or SSM with refractory symptoms due to mast cell mediator release or bone disease not responsive to anti-mediator drug therapy or bisphosphonates.⁹²

The advanced SM (comprising patients with ASM, SM-AHN and MCL) treatment with midostaurin has been shown to deliver good results in an open-label study with 116 patients,⁹³ with a 60% overall response rate, but no difference in the response according to the disease subtype. The dose reduction, owing to toxic effects, occurred in 56% of the patients and the re-escalation to the starting dose was feasible in 32% of those patients. Another phase II study⁹⁴ evaluated 26 ASM patients treated with midostaurin; after 10 years of follow-up, in addition to the 69% response rate in the first report,⁹⁵ 2 others achieved complete responses with continuing treatment. The responses were durable and associated with symptom improvement and significant decreases in bone marrow MC burden and serum tryptase levels. In comparison to historical controls, it has been suggested that midostaurin prolongs overall and progression-free survival.⁴ Low-grade gastrointestinal symptoms were the most common adverse reactions and were manageable with symptomatic treatment. Overall, treatment with midostaurin reduces disease burden, as demonstrated by a decrease in serum tryptase and MC numbers and reduced spleen size in patients with splenomegaly.⁹⁵ In a phase 2 trial with 116 patients,⁹⁶ midostaurin also improved symptoms related to SM, with a decrease in symptom prevalence. The median progression-free survival was 14.1 months and the median overall survival, 33.1 months.

To date, despite no randomized clinical trials comparing midostaurin to other cytoreductive agents, a non-randomized

Table 5 – Cytoreductive agents in systemic mastocytosis.

Drug	Mechanism of action	Dose, route of administration	Overall response rate	Year, ref.
Interferon	Probably inhibits the degranulation of mast cells.	1.2 to 5 million units subcutaneous or intramuscular (3 times weekly) combination with corticosteroids	49 to 53%	2009 ⁸⁷ 2011 ⁹⁰ 2017 ⁸⁸
Cladribine	Synthetic purine analogue cytoreductive	0.13 to 0.17 mg/kg in infusion or subcutaneously, days 1-5; repeated at 4 - 12 weeks until 9 courses	50 to 55%	2009 ⁹¹ 2015 ⁹⁰ 2018 ⁸⁹
Imatinib	Inhibitor type II of protein tyrosine kinases, such as ABL1, PDGFR, ARG and KIT (resistant to D816V mutation)	100 to 400 mg orally twice daily	35 to 50%	2006 ⁸³ 2009 ⁸⁴ 2019 ⁸⁶
Midostaurin	Type I multikinase inhibitor that inhibits the protein product of KIT	100 mg orally twice daily	60 to 69%	2016 ⁹³ 2018 ⁹⁴
Avapritinib	Type I multikinase inhibitor with highly selective and potent activity against mutated KIT (including D816V)	200 mg orally once daily	75%	2021 ⁹⁷

No evidence for increased risk for vaccination, precautions due to high mast cell burden (low risk):

- Patients without previous anaphylaxis or anaphylaxis to a well-defined trigger (eg, hymenoptera venom) and no reactions to medications containing polyethylene glycol
- Routine vaccination in outpatient setting with emergency awareness and emergency medication available for resuscitation
- **Supervision for 30 minutes after vaccination**
- Patient carries unexpired adrenaline autoinjector at the vaccination site
- Premedication with sedating or nonsedating H1 antihistamine may be considered 30-60 minutes prior to vaccination.

No evidence for increased risk for vaccination, precautions due to increased mast cell burden and prior reactions (mild risk):

- Patients with prior anaphylactic reactions with triggers or without known triggers (idiopathic anaphylaxis), but not to polyethylene glycol
- Patients with previous reactions (eg, local redness, fever, generalized malaise) to other vaccines, but no anaphylaxis
- Routine vaccination in outpatient setting with emergency awareness and emergency medication available for resuscitation
- **Supervision for 30-60 minutes after vaccination**
- Patient carries unexpired adrenaline autoinjector to the vaccination site
- Premedication with sedating or nonsedating H1 antihistamine should be considered 30-60 minutes prior to vaccination.

High-risk population

- Patients with Brighton consensus anaphylactic reaction grade 1 and 2 to the first dose of COVID -19 vaccine
- Patients with known or suspected allergy to polyethylene glycol or polysorbate 80/20
- Patients with previous anaphylaxis to vaccination
- Unstable patients with mastocytosis and severe uncontrolled MCAS symptoms
- Allergy evaluation recommended prior to vaccination
- Skin test to PEG and polysorbate 80/20 and vaccine
 - avoidance of vaccines containing PEG if positive skin test
 - vaccination in hospital setting recommended with resuscitation capabilities, emergency awareness if negative skin tests.
- **Supervision for 60 minutes after vaccination**
- Patient carries nonexpired adrenaline autoinjector to the site of vaccination
- Premedication with sedating or nonsedating H1 antihistamine should be done 30-60 minutes prior to vaccination

Figure 2 – ECNM/AIMCD consensus guidelines¹⁰⁰ for COVID-19 Vaccine Risk Stratification in Mastocytosis.

***These recommendations are based on expert opinion and have not been evaluated regarding effectiveness. MCAS, mast cell activation syndrome; PEG, polyethylene glycol.**

comparison of midostaurin to a historical cohort suggested improvement in survival outcomes with this agent.⁹⁷

At the time of the writing of this article, avapritinib, a new tyrosine-kinase inhibitor approved by the FDA in the USA for SM therapy, was not currently available in Brazil.⁹⁸ Table 5 shows the cytoreductive agents used for Systemic Mastocytosis.

Recommendation: The cytoreductive therapy is indicated for patients with advanced systemic mastocytosis and for patients with indolent or smouldering Systemic Mastocytosis, for whom symptom therapy fails. There are no randomized trials of different cytoreductive agents that are commercially available in Brazil. The cladribine, IFN- α and midostaurin are

appropriate first-line therapeutic choices for cytoreductive therapy (GRADE 5).

The allogeneic stem cell transplantation should be considered as the treatment for patients with advanced SM. The decision to proceed to the allogeneic stem cell transplantation should be individualized for each case, considering the patient age and comorbidities, disease prognosis (expected survival inferior to 5 years), donor availability and the prognosis of the associated hematological neoplasm in patients with SM-AHN.^{48,92}

Recommendation: The allogeneic stem cell transplantation should be considered in eligible patients with advanced SM with an estimated survival of fewer than 5 years and/or patients with SM-AHN with hematological neoplasms who have an indication for allogeneic stem cell transplantation (GRADE 4).

In patients with SM-AHN, clinical, histological and molecular data should be integrated to assess which component requires more immediate treatment.⁴ Briefly, in patients with associated aggressive neoplasms, such as advanced myelodysplastic syndrome or acute myeloid leukaemia, the treatment should focus on the associated neoplasm. If symptoms and complications are deemed to be related to the SM, the treatment should focus on the SM component.

Recommendation: For patients with SM-AHN, the treatment focus should be the most symptomatic disease, considering the allogeneic stem cell transplant, based on the disease risk and comorbidities (GRADE 5).

Response criteria for the SM treatment have recently been reviewed.⁹⁹ The most recent models (the IWG-MRT-ECNM and modified IWG-MRT-ECNM) were developed to build upon and overcome the limitations of the prior response criteria.¹⁰⁰ The IWG criteria include comprehensive definitions of organ damage eligible for the response evaluation, using the CTCAE grading; the organ dysfunction is required to be grade 2 and specific criteria for clinical improvement are defined.

Suggestion: The criteria for response should be individualized, taking into consideration the "C" findings, serum trypsin, D816V allele burden, bone marrow mastocyte infiltration and quality of life (GRADE 4).

Vaccination

The European Competence Network on Mastocytosis and American Initiative in Mast Cell Diseases analyzed the risk-benefit ratio of the SARS-CoV-2 vaccination in patients with SM. It was concluded that there is no evidence that the incidence and severity of the reactions to the available vaccines are higher in patients with SM.¹⁰¹ Three risk categories were identified (Figure 2).

A retrospective study¹⁰² of 35 children and 78 adult patients with mastocytosis analyzed clinical and vaccination records and found that children had a higher rate of local and/or systemic adverse reactions; all the cases were self-limiting and the patients recovered after symptomatic treatment. All the adults tolerated the vaccines without adverse events.

Recommendation: Vaccination, including the one against COVID-19, is indicated for all patients after prophylaxis with antihistamines on the same day (GRADE 4).

Conclusions

The systemic mastocytosis comprises a group of mast-cell clonal diseases that range from indolent forms to more aggressive forms accompanied by hematological neoplasms, in which the gain-of-function KIT D186V mutation is the most frequent genomic finding. The disease is underdiagnosed and associated with high morbidity, including an increased risk of anaphylaxis and osteoporosis. Independent of the SM type, the symptom control is the mainstay of the therapy; the advanced forms should also receive cytoreductive therapy.

Funding

Funding to support the expert meeting and the preparation of this manuscript was provided by Novartis. The authors take full responsibility for the content and conclusions stated in this manuscript.

Author contributions

EDRPV, GAP, AMMC, FPSS and PGB performed the literature research and prepared the questions for voting. All authors participated in the meeting and voting, reviewed the manuscript and approved the final version.

Conflicts of interest

AMMC, AMS, AFS, FT, FLN, GFP, JLB, LLM, LFE, MGB and MVA declare no conflicts of interest. EDRPV has received research grants from Novartis, AbbVie and Onconova and presented scientific data in on behalf of Celgene and Novartis. FPSS has received research grants from Novartis, participated in advisory boards at Novartis and presented scientific data on behalf of Novartis, BMS, Amgen, AbbVie, Pfizer and Astellas. FSS has participated in advisory boards at Novartis. GAP has participated in advisory boards and presented scientific data on behalf of Novartis. KBBP has participated in advisory boards at Novartis, Astellas and GSK and presented scientific data on behalf of Novartis, Pintpharma, Wyeth, Janssen and EMS. PGB has participated in advisory boards at Novartis, Sanofi, AstraZeneca and Takeda. RCA has presented scientific data on behalf of Novartis.

Acknowledgments

The authors would like to thank Ana Beatriz Studart (Department of Pathology at the HC-FMUSP), Luciana Nardinelli (Molecular Biology Laboratory of the Hematology Service at the HC-FMUSP) and Daniel Silva Nogueira (flow cytometry laboratory at the HC-FMUSP) for providing photographic documentation and Dr Mariangela Correa, MD, PhD for providing writing assistance on behalf of Springer Healthcare. The authors also express gratitude towards Novartis for the

support of the mastocytosis research. This manuscript was prepared according to the International Society for Medical Publication Professionals–Good Publication Practice for Communicating Company-Sponsored Medical Research: the GPP3 Guidelines.

Supplementary materials

Supplementary material associated with this article can be found in the online version at [doi:10.1016/j.htct.2022.04.006](https://doi.org/10.1016/j.htct.2022.04.006).

REFERENCES

- Valent P, Akin C, Hartmann K, Nilsson G, Reiter A, Hermine O, et al. Advances in the classification and treatment of mastocytosis: current status and outlook toward the future. *Cancer Res.* 2017;77(6):1261–70.
- Soverini S. Improving prognostication and management of systemic mastocytosis. *Lancet Haematol* março de. 2021;8(3):e164–6.
- OCEBM Levels of Evidence Working Group*. OCEBM Levels of Evidence Working Group*. “The Oxford 2011 Levels of Evidence”. [Internet]. Oxford Centre for Evidence-Based Medicine. Available in: <http://www.cebm.net/index.aspx?o=5653>
- Pardanani A. Systemic mastocytosis in adults: 2021 update on diagnosis, risk stratification and management. *Am J Hematol.* 2021;96(4):508–25.
- Valent P, Akin C, Metcalfe DD. Mastocytosis: 2016 updated WHO classification and novel emerging treatment concepts. *Blood.* 2017;129(11):1420–7.
- Fernandes IC, Teixeira M dos A, Freitas I, Selores M, Alves R, Lima M. Adult mastocytosis: a review of the Santo António Hospital’s experience and an evaluation of World Health Organization criteria for the diagnosis of systemic disease. *An Bras Dermatol.* 2014;89(1):59–66.
- Sotlar K, Fridrich C, Mall A, Jaussi R, Bültmann B, Valent P, et al. Detection of c-kit point mutation Asp-816 → Val in microdissected pooled single mast cells and leukemic cells in a patient with systemic mastocytosis and concomitant chronic myelomonocytic leukemia. *Leuk Res.* 2002;26(11):979–84.
- Arock M, Sotlar K, Akin C, Broesby-Olsen S, Hoermann G, Escribano L, et al. KIT mutation analysis in mast cell neoplasms: recommendations of the European competence network on mastocytosis. *Leukemia.* 2015;29(6):1223–32.
- Brockow K. Epidemiology, prognosis, and risk factors in mastocytosis. *Immunol Allergy Clin N Am.* 2014;34(2):283–95.
- Méni C, Bruneau J, Georgin-Lavialle S, Peuffelhous LLS, Damaj G, Hadj-Rabia S, et al. Paediatric mastocytosis: a systematic review of 1747 cases. *Br J Dermatol.* 2015;172(3):642–51.
- Soter NA. Mastocytosis and the skin. *Hematol Oncol Clin N Am.* 2000;14(3):537–55.
- Matito A, Azaña JM, Torrelo A, Alvarez-Twose I. Cutaneous mastocytosis in adults and children: new classification and prognostic factors. *Immunol Allergy Clin N Am.* 2018;38(3):351–63.
- Sandru F, Petca R-C, Costescu M, Dumitraşcu MC, Popa A, Petca A, et al. Cutaneous mastocytosis in childhood-update from the literature. *J Clin Med.* 2021;10(7).
- Hartmann K, Escribano L, Grattan C, Brockow K, Carter MC, Alvarez-Twose I, et al. Cutaneous manifestations in patients with mastocytosis: consensus report of the european competence network on mastocytosis; the american academy of allergy, asthma & immunology; and the European Academy of Allergy and Clinical Immunology. *J Allergy Clin Immunol.* 2016;137(1):35–45.
- Raimondo CD, Duca ED, Silivaggio D, Prete MD, Lombardo P, Mazzeo M, et al. Cutaneous mastocytosis: a dermatological perspective. *Australas J Dermatol.* 2021;62(1):e1–7.
- Butterfield JH, Ravi A, Pongdee T. Mast cell mediators of significance in clinical practice in mastocytosis. *Immunol Allergy Clin N Am.* 2018;38(3):397–410.
- Valent P, Bonadonna P, Hartmann K, Broesby-Olsen S, Brockow K, Butterfield JH, et al. Why the 20% + 2 tryptase formula is a diagnostic gold standard for severe systemic mast cell activation and mast cell activation syndrome. *Int Arch Allergy Immunol.* 2019;180(1):44–51.
- Schwartz LB, Irani A-MA. Serum tryptase and the laboratory diagnosis of systemic mastocytosis. *Hematol Oncol Clin N Am.* 2000;14(3):641–57.
- Sperr WR, Jordan J-H, Fiegl M, Escribano L, Bellas C, Dirnhofer S, et al. Serum tryptase levels in patients with mastocytosis: correlation with mast cell burden and implication for defining the category of disease. *Int Arch Allergy Immunol.* 2002;128(2):136–41.
- Platzgummer S, Bizzaro N, Bilò MB, Pravettoni V, Cecchi L, Sargentini V, et al. Recommendations for the use of tryptase in the diagnosis of anaphylaxis and clonal mastcell disorders. *Eur Ann Allergy Clin Immunol.* 2020;52(02):51.
- Valent P, Akin C, Gleixner KV, Sperr WR, Reiter A, Arock M, et al. Multidisciplinary challenges in mastocytosis and how to address with personalized medicine approaches. *Int J Mol Sci.* 2019;20(12).
- Butterfield JH, Li CY. Bone marrow biopsies for the diagnosis of systemic mastocytosis: is one biopsy sufficient? *Am J Clin Pathol.* 2004;121(2):264–7.
- Reichard KK, Chen D, Pardanani A, McClure RF, Howard MT, Kurtin PJ, et al. Morphologically occult systemic mastocytosis in bone marrow: clinicopathologic features and an algorithmic approach to diagnosis. *Am J Clin Pathol.* 2015;144(3):493–502.
- Sánchez-Muñoz L, Alvarez-Twose I, García-Montero AC, Teodosio C, Jara-Acevedo M, Pedreira CE, et al. Evaluation of the WHO criteria for the classification of patients with mastocytosis. *Mod Pathol.* 2011;24(9):1157–68.
- Escribano L, Orfao A, Villarrubia J, Díaz-Agustín B, Cerveró C, Rios A, et al. Immunophenotypic characterization of human bone marrow mast cells. A flow cytometric study of normal and pathological bone marrow samples. *Anal Cell Pathol J Eur Soc Anal Cell Pathol.* 1998;16(3):151–9.
- Morgado JMT, Sánchez-Muñoz L, Teodósio CG, Jara-Acevedo M, Alvarez-Twose I, Matito A, et al. Immunophenotyping in systemic mastocytosis diagnosis: ‘CD25 positive’ alone is more informative than the ‘CD25 and/or CD2’ WHO criterion. *Mod Pathol.* 2012;25(4):516–21.
- Falchi L, Verstovsek S. Kit mutations: new insights and diagnostic value. *Immunol Allergy Clin N Am.* 2018;38(3):411–28.
- Erben P, Schwaab J, Metzgeroth G, Horny H-P, Jawhar M, Sotlar K, et al. The KIT D816V expressed allele burden for diagnosis and disease monitoring of systemic mastocytosis. *Ann Hematol.* 2014;93(1):81–8.
- Bodemer C, Hermine O, Palmérini F, Yang Y, Grandpeix-Guyodo C, Leventhal PS, et al. Pediatric mastocytosis is a clonal disease associated with D816V and other activating c-KIT mutations. *J Invest Dermatol.* 2010;130(3):804–15.
- Álvarez-Twose I, González P, Morgado JM, Jara-Acevedo M, Sánchez-Muñoz L, Matito A, et al. Complete response after imatinib mesylate therapy in a patient with well-differentiated systemic mastocytosis. *J Clin Oncol.* 2012;30(12):e126–9.
- Broderick V, Waghorn K, Langabeer SE, Jeffers M, Cross NCP, Hayden PJ. Molecular response to imatinib in KIT F522C-mutated systemic mastocytosis. *Leuk Res.* 2019;77:28–9.

32. Escribano L, Álvarez-Twose I, Sánchez-Muñoz L, García-Montero A, Núñez R, Almeida J, et al. Prognosis in adult indolent systemic mastocytosis: a long-term study of the Spanish Network on Mastocytosis in a series of 145 patients. *J Allergy Clin Immunol*. 2009;124(3):514–21.
33. Hoermann G, Gleixner KV, Dinu GE, Kundi M, Greiner G, Wimazal F, et al. The KIT D816V allele burden predicts survival in patients with mastocytosis and correlates with the WHO type of the disease. *Allergy*. 2014;69(6):810–3.
34. Foster R, Griffith R, Ferrao P, Ashman L. Molecular basis of the constitutive activity and STI571 resistance of Asp816Val mutant KIT receptor tyrosine kinase. *J Mol Graph Model*. 2004;23(2):139–52.
35. Pardanani A, Ketterling RP, Brockman SR, Flynn HC, Pateroster SF, Shearer BM, et al. CHIC2 deletion, a surrogate for FIP1L1-PDGFRα fusion, occurs in systemic mastocytosis associated with eosinophilia and predicts response to imatinib mesylate therapy. *Blood*. 2003;102(9):3093–6.
36. Martelli M, Monaldi C, De Santis S, Bruno S, Mancini M, Cavo M, et al. Recent advances in the molecular biology of systemic mastocytosis: implications for diagnosis, prognosis, and therapy. *Int J Mol Sci*. 2020;21(11).
37. Sotlar K, Escribano L, Landt O, Möhrle S, Herrero S, Torrelo A, et al. One-step detection of c-kit point mutations using peptide nucleic acid-mediated polymerase chain reaction clamping and hybridization probes. *Am J Pathol*. 2003;162(3):737–46.
38. Ozturk K, Cayci Z, Gotlib J, Akin C, George TI, Ustun C. Non-hematologic diagnosis of systemic mastocytosis: collaboration of radiology and pathology. *Blood Rev*. 2021;45:100693.
39. Van den Wyngaert T, Strobel K, Kampen WU, Kuwert T, van der Bruggen W, Mohan HK, et al. The EANM practice guidelines for bone scintigraphy. *Eur J Nucl Med Mol Imaging*. 2016;43(9):1723–38.
40. Siegert SI, Diebold J, Ludolph-Hauser D, Löhns U. Are gastrointestinal mucosal mast cells increased in patients with systemic mastocytosis? *Am J Clin Pathol*. 2004;122(4):560–5.
41. Jensen RT. Gastrointestinal abnormalities and involvement in systemic mastocytosis. *Hematol Oncol Clin N Am*. 2000;14(3):579–623.
42. Avila NA, Ling A, Worobec AS, Mican JM, Metcalfe DD. Systemic mastocytosis: CT and US features of abdominal manifestations. *Radiology*. 1997;202(2):367–72.
43. Djelbani-Ahmed S, Chandesris MO, Mekinian A, Canioni D, Brouzes C, Hanssens K, et al. FDG-PET/CT findings in systemic mastocytosis: a French multicentre study. *Eur J Nucl Med Mol Imaging*. 2015;42(13):2013–20.
44. Zettinig G, Becherer A, Szabo M, Uffmann M, Dudczak R, Valent P, et al. FDG positron emission tomography in patients with systemic mastocytosis. *Am J Roentgenol*. 2002;179(5):1235–7.
45. Fu Z, Zhang J, Liu M, Li Z, Li Q. Extramedullary involvement of mast cell leukemia detected by 18F-FDG PET/CT. *Clin Nucl Med*. 2016;41(7):578–9.
46. Lim K-H, Tefferi A, Lasho TL, Finke C, Patnaik M, Butterfield JH, et al. Systemic mastocytosis in 342 consecutive adults: survival studies and prognostic factors. *Blood*. 2009;113(23):5727–36.
47. Pardanani A, Shah S, Mannelli F, Elala YC, Guglielmelli P, Lasho TL, et al. Mayo alliance prognostic system for mastocytosis: clinical and hybrid clinical-molecular models. *Blood Adv*. 2018;2(21):2964–72.
48. Consensus Opinion on Allogeneic Hematopoietic Cell Transplantation in Advanced Systemic Mastocytosis | Elsevier Enhanced Reader [Internet]. [citado 20 de junho de 2021]. Available in: <https://reader.elsevier.com/reader/sd/pii/S1083879116300374?token=740608063BEEC9C7929B85707F4F7682306F68E7F9460A01505605661C8047B328511DDCC44A4826C615C8FC34CC71F&originRegion=us-east-1&originCreation=20210621004449>
49. Giannetti A, Filice E, Caffarelli C, Ricci G, Pession A. Mast cell activation disorders. *Med Kaunas Lith*. 2021;57(2).
50. Andersen C.L., Kristensen T.K., Severinsen M.T., Møller M.B., Vestergaard H., Bergmann O.J., et al. Systemic mastocytosis a systematic review. 2012;6.
51. Coltoff A, Mascarenhas J. Relevant updates in systemic mastocytosis. *Leuk Res*. 2019;81:10–8.
52. Brazzelli V, Grassi S, Merante S, Grasso V, Ciccocioppo R, Bossi G, et al. Narrow-band UVB phototherapy and psoralen-ultraviolet A photochemotherapy in the treatment of cutaneous mastocytosis: a study in 20 patients. *Photodermatol Photoimmunol Photomed*. 2016;32(5-6):238–246.
53. Vojvodic A, Vlaskovic-Jovicevic T, Vojvodic P, Vojvodic J, Goldust M, Peric-Hajzler Z, et al. Melanoma and mastocytosis. *Open Access Maced J Med Sci*. 2019;7(18):3050–2.
54. Hägglund H, Sander B, Gülen T, Lindelöf B, Nilsson G. Increased risk of malignant melanoma in patients with systemic mastocytosis? *Acta Derm Venereol*. 2014;94(5):583–4.
55. Schuch A, Brockow K. Mastocytosis and anaphylaxis. *Immunol Allergy Clin N Am*. 2017;37(1):153–64.
56. Bonadonna P, Bonifacio M, Zanotti R. Mast cell disorders in drug hypersensitivity. *Curr Pharm Des*. 2017;22(45):6862–9.
57. Hermans MAW, Arends NJT, Gerth van Wijk R, van Hagen PM, Kluin-Nelemans HC, Oude Elberink HNG, et al. Management around invasive procedures in mastocytosis: an update. *Ann Allergy Asthma Immunol Off Publ Am Coll Allergy Asthma Immunol*. 2017;119(4):304–9.
58. Akin C. Anaphylaxis and Mast cell disease: what is the risk? *Curr Allergy Asthma Rep*. 2010;10(1):34–8.
59. Romantowski J, Górka A, Niedożytko M, Gülen T, Gruchała-Niedożytko M, Niedożytko B, et al. A challenge for allergologist: application of allergy diagnostic methods in mast cell disorders. *Int J Mol Sci*. 2021;22(3).
60. Brockow K, Jofer C, Behrendt H, Ring J. Anaphylaxis in patients with mastocytosis: a study on history, clinical features and risk factors in 120 patients. *Allergy*. 2008;63(2):226–32.
61. Fricker M, Helbling A, Schwartz L, Müller U. Hymenoptera sting anaphylaxis and urticaria pigmentosa: Clinical findings and results of venom immunotherapy in ten patients. *J Allergy Clin Immunol*. 1997;100(1):11–5.
62. González-de-Olano D, Álvarez-Twose I. Insights in anaphylaxis and clonal mast cell disorders. *Front Immunol*. 2017;8:792.
63. Hermans MAW, van der Vet SQA, van Hagen PM, van Wijk RG, van Daele PLA. Low frequency of acetyl salicylic acid hypersensitivity in mastocytosis: the results of a double-blind, placebo-controlled challenge study. *Allergy*. 2018;73(10):2055–62.
64. Giavina-Bianchi P, Gonçalves DG, Zanandrea A, Borges de Castro R, Garro LS, Kalil J, et al. Anaphylaxis to quinolones in mastocytosis: Hypothesis on the mechanism. *J Allergy Clin Immunol Pract*. 2019;7(6):2089–90.
65. Matito A, Morgado JM, Sánchez-López P, Álvarez-Twose I, Sánchez-Muñoz L, Orfao A, et al. Management of anesthesia in adult and pediatric mastocytosis: a study of the Spanish network on mastocytosis (REMA) based on 726 anesthetic procedures. *Int Arch Allergy Immunol*. 2015;167(1):47–56.
66. Bonadonna P, Pagani M, Aberer W, Bilò MB, Brockow K, Elberink HO, et al. Drug hypersensitivity in clonal mast cell disorders: ENDA/EAACI position paper. *Allergy*. 2015;70(7):755–63.
67. Gülen T, Hägglund H, Dahlén B, Nilsson G. High prevalence of anaphylaxis in patients with systemic mastocytosis – a single-centre experience. *Clin Exp Allergy*. 2014;44(1):121–9.
68. Castells M, Butterfield J. Mast cell activation syndrome and mastocytosis: initial treatment options and long-term management. *J Allergy Clin Immunol Pract*. 2019;7(4):1097–106.

69. van der Weide HY, van Westerloo DJ, van den Bergh WM. Critical care management of systemic mastocytosis: when every wasp is a killer bee. *Crit Care*. 2015;19(1):238.
70. Górską A, Niedożytko M, Lange M, Chełmińska M, Niedożytko B, Wasąg B, et al. Risk factors for anaphylaxis in patients with mastocytosis. *Pol Arch Intern Med*. 2015;125(1–2):46–53.
71. Silva de D, Singh C, Muraro A, Worm M, Alviani C, Cardona V, et al. Diagnosing, managing and preventing anaphylaxis: systematic review. *Allergy*. 2021;76(5):1493–506.
72. Jennings S, Russell N, Jennings B, Slee V, Sterling L, Castells M, et al. The mastocytosis society survey on mast cell disorders: patient experiences and perceptions. *J Allergy Clin Immunol Pract*. 2014;2(1):70–6.
73. Jarkvist J, Brockow K, Gülen T. Low frequency of IgE-mediated food hypersensitivity in mastocytosis. *J Allergy Clin Immunol Pract*. 2020;8(9):3093–101.
74. Chiappetta N, Gruber B. The role of mast cells in osteoporosis. *Semin Arthritis Rheum*. 2006;36(1):32–6.
75. Orsolini G, Viapiana O, Rossini M, Bonifacio M, Zanotti R. Bone disease in mastocytosis. *Immunol Allergy Clin N Am*. 2018;38(3):443–54.
76. Rossini M, Zanotti R, Bonadonna P, Artuso A, Caruso B, Schena D, et al. Bone mineral density, bone turnover markers and fractures in patients with indolent systemic mastocytosis. *Bone*. 2011;49(4):880–5.
77. van der Veer E, Arends S, van der Hoek S, Versluijs JB, de Monchy JGR, Oude Elberink JNG, et al. Predictors of new fragility fractures after diagnosis of indolent systemic mastocytosis. *J Allergy Clin Immunol*. 2014;134(6):1413–21.
78. Orsolini G, Gavioli I, Tripi G, Viapiana O, Gatti D, Idolazzi L, et al. Denosumab for the treatment of mastocytosis-related osteoporosis: a case series. *Calcif Tissue Int*. 2017;100(6):595–8.
79. Rossini M, Zanotti R, Viapiana O, Tripi G, Idolazzi L, Biondan M, et al. Zoledronic acid in osteoporosis secondary to mastocytosis. *Am J Med*. 2014;127(11):1127.e1–4.
80. Barete S, Assous N, de GC, Grandpeix C, Feger F, Palmerini F, et al. Systemic mastocytosis and bone involvement in a cohort of 75 patients. *Ann Rheum Dis*. 2010;69(10):1838–41.
81. Rossini M, Zanotti R, Orsolini G, Tripi G, Viapiana O, Idolazzi L, et al. Prevalence, pathogenesis, and treatment options for mastocytosis-related osteoporosis. *Osteoporos Int*. 2016;27(8):2411–21.
82. Tzankov A, Duncavage E, Craig FE, Kelemen K, King RL, Orazi A, et al. Mastocytosis. *Am J Clin Pathol*. 2021;155(2):239–66.
83. Mannelli F. Catching the clinical and biological diversity for an appropriate therapeutic approach in systemic mastocytosis. *Ann Hematol*. 2021;100(2):337–44.
84. Droogendijk HJ, Kluin-Nelemans HJC, van Doormaal JJ, Oranje AP, van de Loosdrecht AA, van Daele PLA. Imatinib mesylate in the treatment of systemic mastocytosis. *Cancer*. 2006;107(2):345–51.
85. Vega-Ruiz A, Cortes JE, Sever M, Manshour T, Quintás-Cardama A, Luthra R, et al. Phase II study of imatinib mesylate as therapy for patients with systemic mastocytosis. *Leuk Res*. 2009;33(11):1481–4.
86. Ustun C, DeRemer DL, Akin C. Tyrosine kinase inhibitors in the treatment of systemic mastocytosis. *Leuk Res*. 2011;35(9):1143–52.
87. Alvarez-Twose I, Matito A, Morgado JM, Muñoz LS-, Jara-Acevedo M, García-Montero A, et al. Imatinib in systemic mastocytosis: a phase IV clinical trial in patients lacking exon 17 KIT mutations and review of the literature. *Oncotarget*. 2016;8(40):68950–63.
88. Weis Bjerrum O. Interferon- α treatment in systemic mastocytosis. *Curr Drug Targets*. 2011;12(3):433–6.
89. Lei D, Akin C, Kovalszki A. Management of mastocytosis in pregnancy: a review. *J Allergy Clin Immunol Pract*. 2017;5(5):1217–23.
90. Barete S, Lortholary O, Damaj G, Hirsch I, Chandesris MO, Elie C, et al. Long-term efficacy and safety of cladribine (2-CdA) in adult patients with mastocytosis. *Blood*. 2015;126(8):1009–16.
91. Lim KH, Pardanani A, Butterfield JH, Li CY, Tefferi A. Cytoreductive therapy in 108 adults with systemic mastocytosis: outcome analysis and response prediction during treatment with interferon-alpha, hydroxyurea, imatinib mesylate or 2-chlorodeoxyadenosine. *Am J Hematol*. 2009;84(12):790–4.
92. Gotlib J, Gerds AT, Bose P, Castells MC, Deininger MW, Gojo I, et al. Systemic mastocytosis, version 2.2019, NCCN clinical practice guidelines in oncology. *J Natl Compr Canc Netw*. 2018;16(12):1500–37.
93. Gotlib J, Kluin-Nelemans HC, George TI, Akin C, Sotlar K, Hermine O, et al. Efficacy and safety of midostaurin in advanced systemic mastocytosis. *N Engl J Med*. 2016;374(26):2530–41.
94. DeAngelo DJ, George TI, Linder A, Langford C, Perkins C, Ma J, et al. Efficacy and safety of midostaurin in patients with advanced systemic mastocytosis: 10-year median follow-up of a phase II trial. *Leukemia*. 2018;32(2):470–8.
95. Gotlib J, DeAngelo DJ, George TI, Corless CL, Linder A, Langford C, et al. KIT inhibitor midostaurin exhibits a high rate of clinically meaningful and durable responses in advanced systemic mastocytosis: report of a fully accrued phase II trial. *Blood*. 2010;116(21).
96. Hartmann K, Gotlib J, Akin C, Hermine O, Awan FT, Hexner E, et al. Midostaurin improves quality of life and mediator-related symptoms in advanced systemic mastocytosis. *J Allergy Clin Immunol*. 2020;146(2):356–66.
97. Chandesris M-O, Damaj G, Canioni D, Brouzes C, Lhermitte L, Hanssens K, et al. Midostaurin in advanced systemic mastocytosis. *N Engl J Med*. 2016;374(26):2605–6.
98. Dhillon S. Avapritinib: first approval. *Drugs*. 10 de março de 2020;80(4):433–9.
99. Shomali W, Gotlib J. Response criteria in advanced systemic mastocytosis: evolution in the era of KIT inhibitors. *Int J Mol Sci*. 2021;22(6).
100. Gotlib J, Pardanani A, Akin C, Reiter A, George T, Hermine O, et al. International Working Group-Myeloproliferative Neoplasms Research and Treatment (IWG-MRT) & European Competence Network on Mastocytosis (ECNM) consensus response criteria in advanced systemic mastocytosis. *Blood*. 2013;121(13):2393–401.
101. Bonadonna P, Brockow K, Niedożytko M, Elberink HO, Akin C, Niedożytko B, et al. COVID-19 vaccination in mastocytosis: recommendations of the European Competence Network on Mastocytosis (ECNM) and American Initiative in Mast Cell Diseases (AIM). *J Allergy Clin Immunol Pract*. 2021; S221321982100386X.
102. Zanoni G, Zanotti R, Schena D, Sabbadini C, Opri R, Bonadonna P. Vaccination management in children and adults with mastocytosis. *Clin Exp Allergy*. 2017;47(4):593–6.