


Case Report

Detection of ABL1 deletion without BCR-ABL rearrangement in ETP-ALL



Ahmed Makboul *, Walaa T. El-Mahdy, Doaa F. Temerik

South Egypt Cancer Institute, Assiut University, Assiut, Egypt

ARTICLE INFO

Article history:

Received 26 June 2021

Accepted 28 January 2022

Available online 25 March 2022

Introduction

Acute lymphoblastic leukemia (ALL) is characterized by proliferation of blasts that are committed to B cell or T cell lineage.¹ A particular challenging subtype is early T cell precursor (ETP)-ALL. ETP-ALL has unique features compared with other subtypes of T-ALL, and has attracted attention due to its refractoriness to chemotherapy.²

The immunophenotype of ETP-ALL is unique and characteristic. Blasts are positive for CD7, CD2, and cytoplasmic CD3. They are also positive for myeloid-associated antigens, such as CD34, CD117, CD13, CD11b and HLA-DR, whereas myeloperoxidase (MPO) is negative and CD4 may be positive in some cases.^{3,4} On the other hand, CD5 is negative/weakly positive (expressed in up to 75% of blasts).⁵ Of note, CD1a and CD8 are typically negative on ETP-ALL blasts.

The Abelson leukemia viral oncogene (ABL1), located at 9q34, is a proto-oncogene with tyrosine kinase activity. Its constitutive activation can occur via a BCR-ABL1 fusion gene generated by t(9;22). The phenomenon of ABL1 gene

deletion without BCR-ABL1 rearrangement in ALL patients is rarely reported.¹ Up to now, only six cases of ABL1 deletion have been reported in previous literature and all of these cases were reported in B cell ALL. Here, we discuss the first case of ETP-ALL that shows ABL1 deletion, without BCR-ABL1 rearrangement, detected by fluorescence in situ hybridization (FISH).

Case report

A 4-year-old male child presented with fatigue and pallor for 2 weeks. The patient had no organomegaly and lymphadenopathy. Initial complete blood count showed a hemoglobin level of 6.3 g/dL, a platelet count of $11 \times 10^9/L$ and a white blood cell count of $324 \times 10^9/L$ with presence of 95% blasts (Figure 1). Bone marrow (BM) aspiration revealed 98% blasts. Flow cytometric immunophenotyping revealed that the blasts (CD45 dim) were positive for cytoplasmic CD3, CD34, CD33, CD2, CD7, HLA-DR and CD117. They were negative for CD4, CD8, CD1a and cytoplasmic MPO. CD5 is weakly positive. These findings diagnosed the case as ETP-ALL.

Cytogenetic testing was performed using ALL FISH panel that includes BCR-ABL1, KMT2A-AFF1, TEL-AML1, E2A-PBX1 dual fusion probes, MYC rearrangement and IGH rearrangement break apart probes (CytoCell Ltd, Oxford Gene Technology, UK).

* Corresponding author at: Assistant lecturer in Cytogenetics Unit, Clinical Pathology Department, South Egypt Cancer Institute, Assiut University, Assiut, 71111, Egypt.

E-mail address: a.makboul@aun.edu.eg (A. Makboul).

<https://doi.org/10.1016/j.htct.2022.01.016>

2531-1379/© 2022 Associação Brasileira de Hematologia, Hemoterapia e Terapia Celular. Published by Elsevier España, S.L.U. This is an open access article under the CC BY-NC-ND license (<http://creativecommons.org/licenses/by-nc-nd/4.0/>).

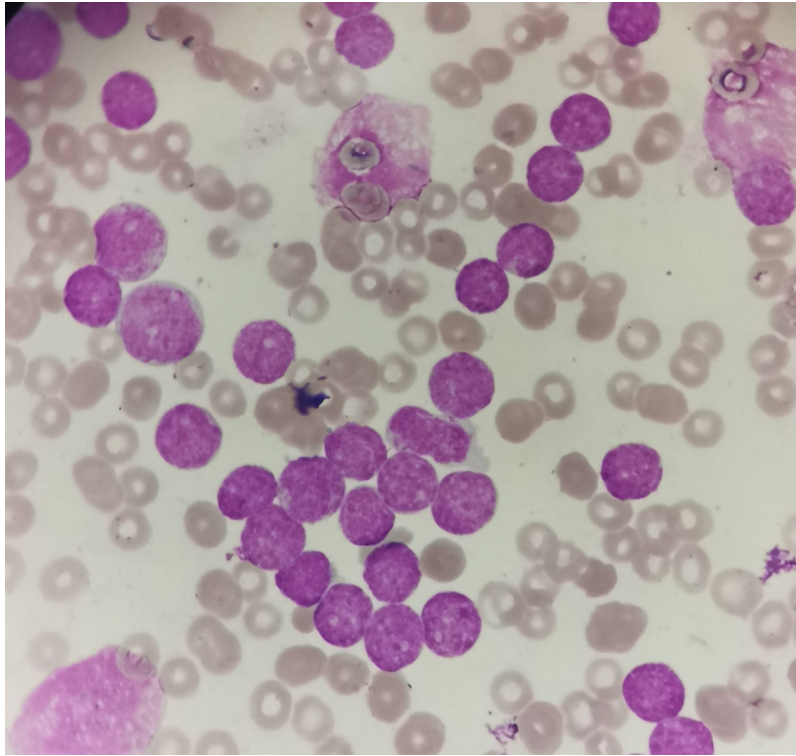


Figure 1 – Blast morphology in our case. They are variable sized, high nuclear to cytoplasmic ratio and condensed nuclear chromatin.

FISH analysis was performed using Zeiss Axio Imager.Z2 fluorescent microscope (Carl Zeiss MicroImaging GmbH, Munich, Germany) equipped with Metafer Slide Scanning System (MetaSystems GmbH, Altlussheim, Germany). A total of 200 interphase nuclei were scored. Analysis of BCR-ABL1 translocation dual fusion probe showed one red and two green signals in 90% of interphases indicating ABL1 deletion (Figure 2). No MYC rearrangement, IGH rearrangement KMT2A-AFF1, E2A-PBX1 or TEL-AML1 translocation were detected in examined interphases.

Follow up

The patient received induction chemotherapy. Post-induction day 15 bone marrow examination revealed 89% blasts. FISH

was done using BCR-ABL1 dual fusion probe and revealed the same abnormality detected in baseline evaluation in 80% of examined interphases. The patient was lost to follow-up.

Discussion

ABL1 deletion from chromosome 9 without t(9;22) has been previously reported in a very few cases of B-cell ALL.^{1,6-8} To the best of our knowledge, this is the first case of ETP-ALL with ABL1 deletion detected by FISH. It is not well known whether the ABL1 deletion in our case has a role in leukemogenesis or whether it represents an underlying genetic instability.

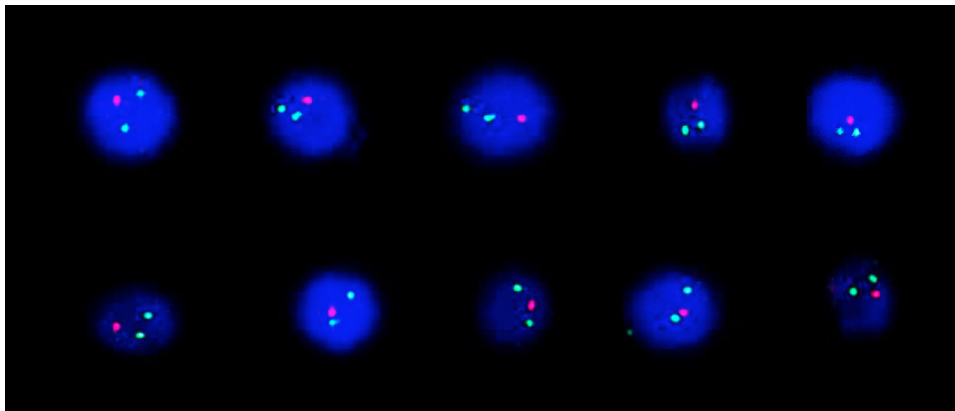


Figure 2 – Interphase nuclei showing 1 red and 2 green signals indicating ABL1 deletion.

The main function of ABL1 is that it prevents the development of tumors by protecting the tumor suppressor gene p53 from degradation.⁹ When ABL1 gene is deleted, this results in degradation of tumor suppressor gene p53 and this contributes to leukemogenesis. ABL1 can also suppress the development of tumors by regulating the oncogenic transforming growth factor- β (TGF- β) signaling.¹⁰ ABL1 activation can block TGF- β tumor-promoting signals and thus, restoring a tumor-suppressing microenvironment. TGF- β up-regulates matrix metalloproteinases (MMPs) significantly, in especial MMP-9 and MMP-13, to enhance the invasion of tumor cells. ABL activation, however, can suppress the expression and secretion of MMPs through inhibiting TGF- β signaling. Therefore, this may be another mechanism to explain the occurrence of malignant tumors in patients with ABL1 deletion.⁸

Conclusion

ABL1 deletion was not previously reported in ETP-ALL. It is believed to be a very rare phenomenon. To the best of our knowledge, this is the first case of ETP-ALL, showing ABL gene deletion. Presence of ABL1 deletion may contribute to poor response to chemotherapy and therefore, the clinical significance of ABL1 gene deletion in ETP-ALL needs to be clarified.

Authors' contribution

Authors Doaa F. Temerik, Walaa T. El-Mahdy and Ahmed Makboul analyzed the case. Author Ahmed Makboul wrote the manuscript. Author Doaa F. Temerik revised the manuscript.

Conflicts of interest

The authors declare that they have no competing interests.

REFERENCES

1. Kim MJ, Yoon HS, Lim G, Kim SY, Lee HJ, Suh JT, et al. ABL1 gene deletion without BCR/ABL1 rearrangement in a young adolescent with precursor B-cell acute lymphoblastic leukemia: clinical study and literature review. *Cancer Genet Cytogenet.* 2010;196(2):184–8.
2. Castaneda Puglianini O, Papadantonakis N. Early precursor T-cell acute lymphoblastic leukemia: current paradigms and evolving concepts. *Ther Adv Hematol.* 2020;11:204062072092947.
3. Wang P, Peng X, Deng X, Gao L, Zhang X, Feng Y. Diagnostic challenges in T-lymphoblastic lymphoma, early T-cell precursor acute lymphoblastic leukemia or mixed phenotype acute leukemia: a case report. *Medicine.* 2018;97(41).
4. Arber DA, Orazi A, Hasserjian R, Thiele J, Borowitz MJ, Le Beau MM, et al. The 2016 revision to the World Health Organization classification of myeloid neoplasms and acute leukemia. *Blood.* 2016;127(20):2391–405.
5. Chopra A, Bakhshi S, Pramanik SK, Pandey RM, Singh S, Gajendra S, et al. Immunophenotypic analysis of T-acute lymphoblastic leukemia. A CD5-based ETP-ALL perspective of non-ETP T-ALL. *Eur J Haematol.* 2014;92(3):211–8.
6. Lee DS, Lee YS, Yun Y sook, Kim YR, Jeong SS, Lee YK, et al. A study on the incidence of ABL gene deletion on derivative chromosome 9 in chronic myelogenous leukemia by interphase fluorescence in situ hybridization and its association with disease progression. *Genes Chromosom Cancer.* 2003;37(3):291–9.
7. Huh J, Moon H, Chung W. A case of ABL deletion in a patient with precursor B cell lymphoblastic leukemia. *Ann Hematol.* 2008;87:239–41. Springer.
8. Jiang Y, Zhang J, Guo D, Zhang C, Hong L, Huang H, et al. Entire ABL1 gene deletion without BCR/ABL1 rearrangement in a female patient with B-Cell precursor acute lymphoblastic leukemia. *Onco Targets Ther.* 2020;13:783–90.
9. Levav-Cohen Y, Goldberg Z, Zuckerman V, Grossman T, Haupt S, Haupt Y. C-Abl as a modulator of p53. *Biochem Biophys Res Commun.* 2005;331:737–49. Academic Press Inc..
10. Pardali K, Moustakas A. Actions of TGF- β as tumor suppressor and pro-metastatic factor in human cancer. *Biochimica et Biophysica Acta - Rev Cancer. Biochim Biophys Acta.* 2007;1775:21–62.