





Case Report

COVID-19 presenting as a viral exanthem and detected during admission prescreening in a hematopoietic cell transplant recipient



Nausheen Ahmed ^{a,b}, Marcos de Lima ^{a,b}, Bethany R. Rohr ^{b,c}, Benjamin K. Tomlinson ^{a,b,*}

^a University Hospitals Seidman Cancer Center, Cleveland, OH, USA

^b Case Western Reserve University, Cleveland, OH, USA

^c University Hospitals Cleveland Medical Center, Cleveland, OH, USA

ARTICLE INFO

Article history:

Received 4 June 2020

Accepted 8 June 2020

Available online 13 June 2020

Introduction

Patients with active cancer are vulnerable to the severe acute respiratory syndrome coronavirus 2 (SARS-CoV-2) infection and are at risk for rapid deterioration and high mortality.^{1,2} Immunocompromised patients, such as hematopoietic cell transplant (HCT) recipients and cellular therapy candidates, may have increased vulnerability. As of April 23, 2020, the European Society for Blood and Marrow Transplantation and the Center for International Blood and Marrow Transplant Research have publicly reported 70 cases of post-HCT transplant coronavirus disease-19 (COVID-19).^{3,4} As a result of the high mortality in this population, the American Society of Transplantation and Cellular Therapy (ASTCT) recently published guidelines on March 18, 2020, suggesting universal testing of patients before admission for cellular therapy or stem cell transplant to mitigate the risk of transmission and outbreaks in transplant wards.⁵ Accordingly, at our institution

a policy to screen all patients planned for HCT or cellular therapy the day prior to admission with a nasopharyngeal swab real-time reverse transcriptase-polymerase chain reaction (RT-PCR) for SARS-CoV-2 infection was implemented. The RT-PCR tests at our facility may target one of three regions in the viral genome for amplification, depending on the day-to-day availability of testing and reagents: the nucleocapsid genes, the S and ORF1ab genes, or the RdRP gene. On the first day of the policy implementation, we identified our first case of Covid-19 in a patient without suspicious symptoms.

Case

The patient is a 33-year-old woman with diabetes and therapy-related myelodysplasia (tMDS) who is twelve months status post-allogeneic HCT. Her tMDS relapsed within six months of the transplant and was unresponsive to post-HCT azacitidine, immunosuppression withdrawal and donor lymphocyte

* Corresponding author at: Stem Cell Transplant, University Hospitals, Seidman Cancer Center/Case Western Reserve University School of Medicine, 11100 Euclid Avenue, Humphrey Building/B700, Cleveland, OH 44106, USA.

E-mail address: Benjamin.Tomlinson@UHhospitals.org (B.K. Tomlinson).

<https://doi.org/10.1016/j.htct.2020.06.002>

2531-1379/© 2020 Associação Brasileira de Hematologia, Hemoterapia e Terapia Celular. Published by Elsevier Editora Ltda. This is an open access article under the CC BY-NC-ND license (<http://creativecommons.org/licenses/by-nc-nd/4.0/>).

infusions. At approximately T + 110 post-HCT, she developed an erythematous rash on the backs of her wrists, forearms, knees and feet, which resolved within a month with topical treatment with triamcinolone cream and tacrolimus cream, and was attributed to graft-versus-host disease (GVHD). Her GVHD history included grade 1 upper and lower gastrointestinal involvement, which was successfully treated with steroids. She had recently been tapered off tacrolimus for graft-versus-host disease (GVHD) at approximately T + 340.

As a result of her disease relapse, the patient was planned for admission to receive the natural killer cell therapy in a clinical trial. Two weeks before admission (T + 356), she had a COVID-19 interview screen prior to a routine clinical appointment. Such screening is now standard for all patients entering our institution. At the time, she reported vigilant social

distancing and no respiratory symptoms. A review of systems was notable for chronic intermittent diarrhea and a week-long history of a pruritic skin rash; both were distinct from her prior GVHD symptoms. She was otherwise well, with no respiratory symptoms. Upon examination, her temperature was 37.3°C and oxygen saturation was 99%. The examination of her skin revealed pink erythematous patches on her trunk (Figure 1). The laboratory evaluation demonstrated stable pancytopenia, without neutropenia or lymphopenia. The skin biopsy from her right back to rule out GVHD demonstrated a very mild superficial perivascular lymphocytic infiltrate, without notable eosinophils, and a mild perifollicular lymphocytic infiltrate with parakeratosis overlying follicles (Figure 2). The histologic findings were suggestive of a viral exanthem. During the pre-appointing screening, she did not meet institutional

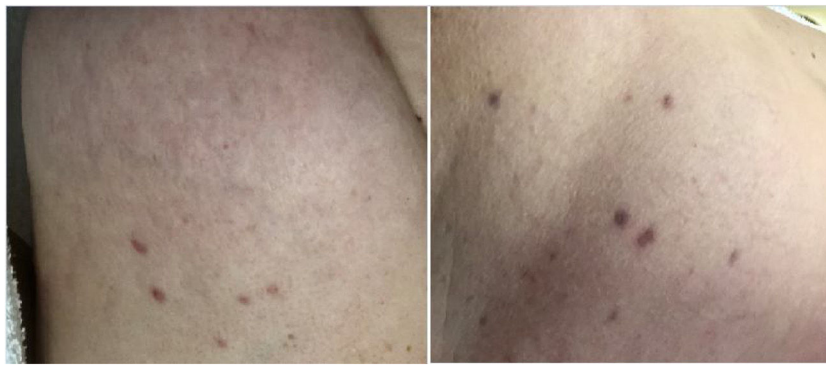


Figure 1 – Faint pink erythematous slightly reticular patches involving the flanks. The brown papules and macules are long standing melanocytic nevi.

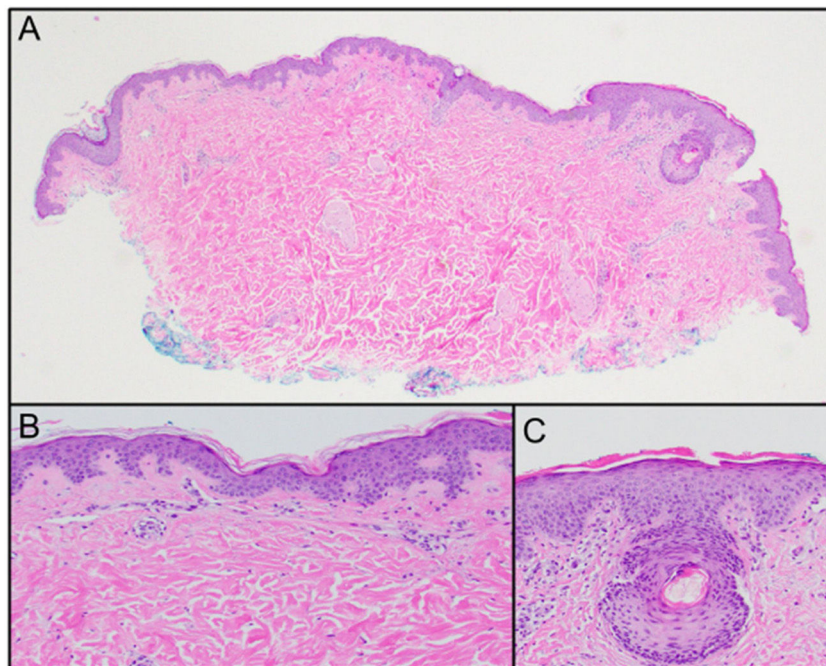


Figure 2 – (A) Scanning magnification reveals a punch biopsy specimen with a very mild superficial perivascular infiltrate. A follicle is present with a mild perifollicular lymphocytic infiltrate with overlying parakeratosis (20× magnification, H&E). (B) Higher magnification of the scant superficial perivascular lymphocytic infiltrate. Eosinophils were not identified (H&E, 100× magnification). (C) Higher magnification of the mild perifollicular lymphocytic infiltrate with overlying parakeratosis and mild follicular spongiosis. The Periodic Acid Schiff (PAS) stain was negative (H&E, 100× magnification).

criteria for the SARS-CoV-2 testing at the time of biopsy, in part due to triage algorithms designed to conserve available test kits. Her therapeutic plan included clinical trial enrollment and a plan to admit for conditioning chemotherapy in two weeks.

A day before her planned admission (T + 370), she received the COVID-19 testing per the newly implemented policy and had a positive test for SARS-CoV-2. She was afebrile with no new symptoms and reported improvement, but not resolution, of her rash. Her chemotherapy was therefore postponed and the patient started two weeks of home isolation with remote interactions. Two weeks later (T + 384), she continued to report no respiratory symptoms and reported no further diarrhea. Upon examination, she was afebrile and again found to have complete resolution of the rash. Two SARS-CoV-2 PCR tests on T + 384 and T + 385 were negative and she was ready to proceed with the planned procedure.

The patient's positive test and improving clinical course suggest that her prior presentation was an atypical presentation of COVID-19. This is further supported by the histologic findings of her skin biopsy.

Discussion

Patients with cancer have a higher chance of acquiring the SARS-CoV-2 infection than those without cancer and have a higher likelihood of severe events, such as admission to the intensive care unit, requiring mechanical ventilation.¹ The HCT recipients are likely at higher risk of morbidity and mortality, given systemic immunosuppression and delayed immune reconstitution, as has been demonstrated in solid tumor transplant recipients.⁶

The most common symptoms of COVID-19 are respiratory symptoms and fever and the few early reports suggest this presentation is also the most common in the HCT recipients.^{3,7} The skin rash appears to be a much less common presentation. In China, out of 1099 patients, only 2 presented with a skin rash.⁸ The skin rash, such as livedo reticularis and petechial rash have been reported, but our patient's positive SARS-CoV-2 test and biopsy suggest COVID-19 may also cause a more classic viral exanthem.^{9,10}

This atypical presentation of COVID-19 poses a diagnostic challenge in post-HCT patients due to potential misdiagnosis as GVHD. This patient's case was only identified due to rational screening policies, which prevented the initiation of immunosuppressive chemotherapy in a patient with active disease. Transplant physicians will need to have a very high level of suspicion during this pandemic to protect their population. Although there are now numerous examples of asymptomatic patients, we believe this to be the first report of a screening diagnosing COVID-19 in an HCT recipient.¹¹ Critically, our case

illustrates the importance of heeding ASTCT recommendations for diligent SARS-CoV-2 testing prior to admissions to high-risk wards. Such measures may be essential to reduce exposure of other immunocompromised patients and health care workers during the pandemic.

Conflicts of interest

Marcos de Lima: consultant for Pfizer, Incyte and BMS.

Nausheen Ahmed: None.

Benjamin K. Tomlinson: None.

Bethany R. Rohr: None.

REFERENCES

- Liang W, Guan W, Chen R, Wang W, Li J, Xu K, et al. Cancer patients in SARS-CoV-2 infection: a nationwide analysis in China. *Lancet Oncol.* 2020;21(3):335–7.
- Ueda M, Martins R, Hendrie PC, McDonnell T, Crews JR, Wong TL, et al. Managing cancer care during the COVID-19 pandemic: agility and collaboration toward a common goal. *J Natl Comprehens Cancer Netw.* 2020:1–4.
- Sahu KK, Jindal V, Siddiqui AD. Facing COVID-19 in the hematopoietic cell transplant setting: a new challenge for transplantation physicians. *Blood Cells Mol Dis.* 2020:102439.
- CIBMTR. COVID-19 updates COVID-19 reported data; 2020 [accessed 23.04.20].
- Bennett E. ASTCT interim guidelines for COVID-19 management in hematopoietic cell transplant and cellular therapy patients version 1.2 [Internet]. Available from: <https://www.astct.org/viewdocument/astct-interim-patient-guidelines-ma?CommunityKey=d3949d84-3440-45f4-8142-90ea05adb0e5&tab=librarydocuments.%202020>
- Akalin E, Azzi Y, Bartash R, Seethamraju H, Parides M, Hemmige V, et al. COVID-19 and kidney transplantation. *N Engl J Med.* 2020, <http://dx.doi.org/10.1056/NEJMc2011117>. Epub ahead of print.
- European Society for Blood and Marrow Transplantation – EBMT; 2020. Available from: <https://www.ebmt.org/covid-19-and-bmt>
- Guan WJ, Ni ZY, Hu Y, Liang WH, Ou CQ, He JX, et al. Clinical characteristics of coronavirus disease 2019 in China. *N Engl J Med.* 2020;382(18):1708–20.
- Manalo IF, Smith MK, Cheeley J, Jacobs R. A dermatologic manifestation of COVID-19: Transient livedo reticularis [published online ahead of print, 2020 Apr 10]. *J Am Acad Dermatol.* 2020;S0190-9622(20), 30558-2 doi; 10.1016/j.jaad.2020.04.018.
- Joob B, Wiwanitkit V. COVID-19 can present with a rash and be mistaken for dengue. *J Am Acad Dermatol.* 2020;82(5):e177.
- Sutton D, Fuchs K, D'Alton M, Goffman D. Universal screening for SARS-CoV-2 in women admitted for delivery. *N Engl J Med.* 2020;382(22):2163–4.