

Review article

Can dentists detect multiple myeloma through oral manifestations?



Thaís Miranda Xavier de Almeida, Édila Figuerêdo Feitosa Cavalcanti,
Alessandra da Silva Freitas, Roberto José Pessoa de Magalhães, Angelo Maiolino,
Sandra Regina Torres*

Universidade Federal do Rio de Janeiro (UFRJ), Rio de Janeiro, RJ, Brazil

ARTICLE INFO

Article history:

Received 29 March 2017

Accepted 24 August 2017

Available online 24 November 2017

Keywords:

Multiple Myeloma

Oral Manifestations

Mouth

Jaws

ABSTRACT

Objective: To review published data on oral manifestations of multiple myeloma.

Methods: An electronic database search was performed of articles published from 1971 to November 2016 in order to identify studies that reported oral manifestations of patients with multiple myeloma. Case reports and case series with oral manifestations of multiple myeloma in English were included in the study. An additional search was performed of the references of the selected articles.

Results: Thirty-seven articles that reported 81 patients with oral manifestations of multiple myeloma were selected: 30 case reports (82%) and seven case series (18%). The most common clinical features in the dental cavity were swelling (65.4%), bone pain (33.3%), paresthesia (27.1%) and amyloidosis lesions (11.1%). Osteolytic lesions detected on imaging exams were reported in the majority of the patients (90.1%) as plasmacytomas or 'punched-out' lesions.

Conclusions: Swelling and osteolytic lesions represent the most common clinical and radiographic signs of the jaws relating to multiple myeloma, respectively.

© 2017 Associação Brasileira de Hematologia, Hemoterapia e Terapia Celular. Published by Elsevier Editora Ltda. This is an open access article under the CC BY-NC-ND license (<http://creativecommons.org/licenses/by-nc-nd/4.0/>).

Introduction

Multiple myeloma (MM) is a common bone malignancy of unknown etiology that affects mainly older age groups.¹ Nearly 80% of diagnosed MM is preceded by an asymptomatic

pre-malignant stage termed monoclonal gammopathy of undetermined significance (MGUS).² The classical form of MM is characterized by signs such as hyperCalcemia, Renal insufficiency, Anemia, and Bone lesions (CRAB).³ The main clinical signs and symptoms of MM are bone pain (accompanied or not by pathologic fractures), fatigue, infections and secondary

* Corresponding author at: Department of Oral Pathology and Diagnosis, Faculdade de Odontologia, Universidade Federal do Rio de Janeiro (UFRJ), Av. Carlos Chagas Filho 373, Prédio do CCS, Bloco K, 2º andar, Sala 56. Ilha da Cidade Universitária, 21941-902 Rio de Janeiro, RJ, Brazil.

E-mail address: sandratorres@ufrj.br (S.R. Torres).

<https://doi.org/10.1016/j.bjhh.2017.08.006>

2531-1379/© 2017 Associação Brasileira de Hematologia, Hemoterapia e Terapia Celular. Published by Elsevier Editora Ltda. This is an open access article under the CC BY-NC-ND license (<http://creativecommons.org/licenses/by-nc-nd/4.0/>).

amyloidosis.⁴ Commonly, bone lesions may be represented by diffuse or localized osteolytic lesions, named plasmacytomas, or by a ‘punched-out’ pattern.¹ The maxillary and mandibular bones may be affected by these lesions,^{1,5–27} and nearly 35% of patients diagnosed with symptomatic MM present lesions in the jaws.²⁸

It is important that clinical manifestations of MM are recognized at early stages.⁵ Some features of MM may manifest in the oral structures and dentists should be able to detect lesions that may represent oral manifestations of MM during the routine oral clinical and imaging exams that are periodically performed for dental treatment.

The oral signs and symptoms of patients presenting MM are characterized by pain, bleeding, dysphagia, paresthesia and osteolytic lesions.²³ However, literature on the oral manifestations of MM is poor and mainly restricted to cases reports. The aim of this study was to perform a search of the literature on the oral manifestations of MM, highlighting the most common clinical and imaging findings of the oral cavity and related conditions.

Method

An electronic database search of the literature was performed in order to identify studies published from January 1971 to November 2016 that reported oral manifestations in patients with MM. The Pubmed/Medline database was used employing the mesh terms “oral manifestations” (and associated

entry terms “manifestation, oral” and “manifestations, oral”) AND “multiple myeloma”. Study criteria were applied and duplicated articles were eliminated. Clinical and epidemiological studies reporting oral manifestations of MM in English were eligible for the study. Reviews, letters to the editors, papers written in languages other than English, and those not available in the full version were excluded. An additional manual search was made of the references of the primary selection using the same criteria.

Results

Sixty-six different abstracts were found in the electronic database search. Twenty articles were selected after the elimination of articles published in languages other than English ($n=8$), articles published before 1971 ($n=5$), articles that did not address the topic ($n=20$), articles that were not found ($n=2$), and literature reviews ($n=11$). Three hundred and 63 articles were found in the manual search of the references of the selected articles. After applying study criteria to these references, 346 articles were excluded. Thus, 37 studies were selected for this review: 30 case reports (82%), and seven case series (18%). No epidemiological or intervention studies were found in the search. Figure 1 shows the flowchart for the study selection process.

The main clinical and radiographic features found in the 37 selected studies are shown on Table 1. In more than half of the studies (20 studies), these characteristics were

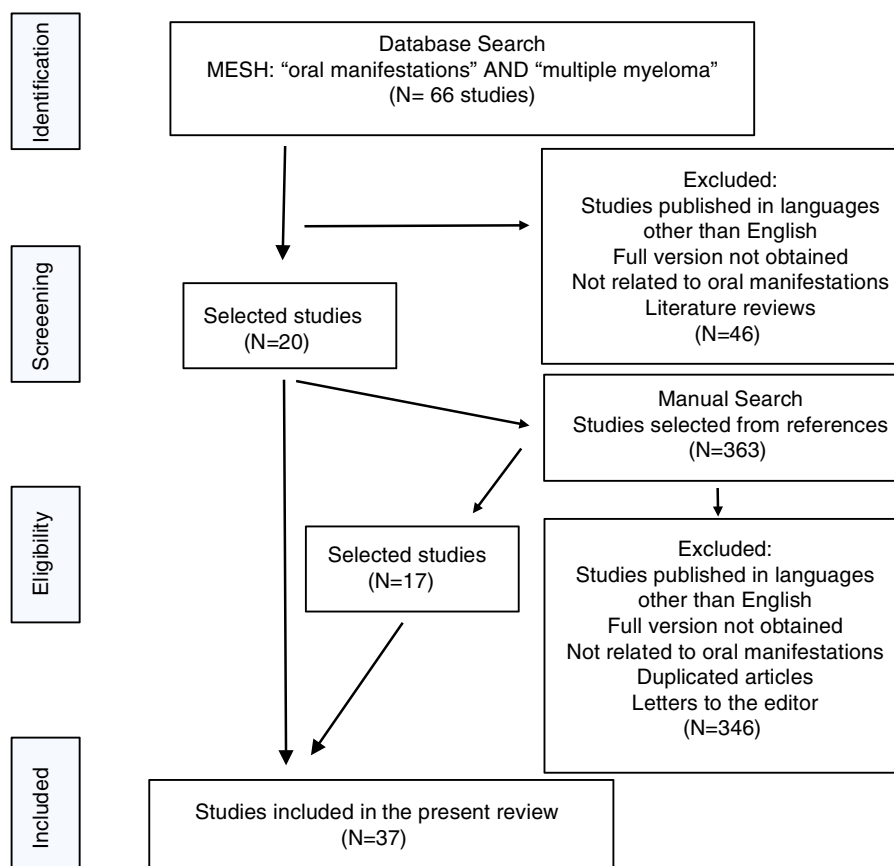


Figure 1 – Flowchart of the study selection process.

Table 1 – Characteristics of studies, population, oral clinical signs and imaging aspects of patients with multiple myeloma reported in the 37 studies.^a

Author	Study type	Sample size/number of patients with oral manifestations	Symptom	Clinical sign	Imaging aspects of lesions	Type of image	First detected sign of MM
Barret et al. ⁸	Case report	1/1	Pain	Swelling	Multiple diffuse lytic	Non specified	No
Yoshimura et al. ⁹	Case report	2/2	Pain	Swelling	Multiple diffuse lytic Punch-out	Skull and periapical radiograph CT	Yes
Kraut et al. ¹⁰	Case report	1/1	Difficulty chewing	Amyloidosis in upper lip	Multiple diffuse lytic	Skull radiograph	No
Flick et al. ⁴⁰	Case report	1/1	None	Amyloidosis in the tongue	–	–	Yes
Salisbury et al. ⁴⁴	Case report	1/1	Pain Bleeding on the buccal mucosa	Amyloidosis in the tongue	–	–	No
Epstein et al. ¹¹	Case report	1/1	Pain Trismus	None	Punch-out lytic with root resorption	Pantomographic radiograph	No
Babajews et al. ⁴¹	Case report	1/1	None	Amyloidosis in the tongue	–	–	Yes
Raubenheimer et al. ⁴²	Case report	1/1	Pain Dysphagia	Amyloidosis in the tongue, Parotid gland and gum Hyposalivation	–	–	Yes
Jacobs et al. ⁴⁵	Case report	1/1	Dyslalia Dysphagia	Amyloidosis in the tongue	–	–	No
Lambertenghi et al. ¹²	Case series	193/10	Pain Paresthesia	Swelling in the mandible (2 cases)	Multiple lytic (9 cases) Single (1 case) Diffuse (8 cases)	Skull radiograph Lateral skull tomogram	No
Tamir et al. ¹³	Case report	3/3	None	Swelling in the mandible Amyloidosis	Multiple lytic	Panoramic radiograph CT	Yes
Reinish et al. ³⁷	Case report	1/1	Dysphagia Pain Xerostomia	Amyloidosis	–	–	Yes
Furutani et al. ¹⁴	Case series	38/5	Pain	Pathological fracture in the mandible (1 case)	Multiple lytic (4 cases) single (1 case)	Skull and panoramic radiographs	No
Lee et al. ⁵	Case report	2/2	Pain Paresthesia in the lower lip	Bleeding gum Tooth mobility	Multiple lytic Punch-out	Panoramic radiograph	Yes
Witt et al. ⁷	Case series	77/12	Paresthesia in the mandible	Bleeding gum	Single lytic (1 case) multiple (11 cases)	Skull, panoramic and periapical radiographs	No
Gray et al. ³¹	Case report	1/1	Pain Paresthesia	Swelling in the left maxilla	Single lytic	Panoramic and periapical radiographs CT	No
Ho et al. ¹⁵	Case report	1/1	None	Swelling in the mandible	Single lytic	CT	No
Mozaffari et al. ¹⁶	Case report	1/1	None	Swelling Gum bleeding	Multiple lytic Punch-out	Skull and panoramic radiographs	Yes
Anacak et al. ¹⁷	Case report	1/1	None	Swelling in the mandible	Single lytic Root resorption	Panoramic radiograph	No

Table 1 – (Continued)

Author	Study type	Sample size/number of patients with oral manifestations	Symptom	Clinical sign	Imaging aspects of lesions	Type of image	First detected sign of MM
Lae et al. ¹⁸	Case series	12/12	None	Swelling Pathological fracture amyloidosis	Multiple lytic	Panoramic radiograph	No
Vucicevic-Boras et al. ⁴³	Case report	1/1	None	Candidiasis	–	–	Yes
Baykul et al. ¹⁹	Case report	1/1	Paresthesia in the mandible	None	Multiple diffuse lytic punch-out	Panoramic and periapical radiograph CT	Yes
Owotade et al. ²⁰	Case series	30/3	None	Bleeding gum Swelling (3 cases)	Multiple lytic	CT	No
Pinto et al. ²¹	Case report	1/1	Pain	Swelling in the maxilla bleeding gum	Single lytic	Periapical radiograph	Yes
Segundo et al. ²²	Case report	1/1	Paresthesia in the lower lip	Swelling	Multiple lytic	Panoramic radiograph CT	Yes
Talamo et al. ⁶	Case series	170/1	None	Amyloidosis in the tongue	–	–	No
Shah et al. ²²	Case report	1/1	None	Swelling in the maxilla tooth mobility	Single lytic	Panoramic radiograph	Yes
Ghosh et al. ²⁴	Case report	1/1	None	Swelling	Lytic	Skull and panoramic radiographs	Yes
Vinayachandran and Sankarapandian ²⁵	Case report	1/1	None	Swelling	Single lytic	Occlusal and panoramic radiograph CT	Yes
Cardoso et al. ²⁶	Case series	5/5	Pain Disphagia Paresthesia Lip anesthesia	Swelling	Multiple lytic (1 case) Single (4 cases)	Panoramic, CBCT, periapical radiographs and MRI	No
Troeltzsch et al. ²⁷	Case report	1/1	None	Tooth mobility in the mandible	Single lytic Root resorption	Non specified	No
Zhao et al. ⁶	Case report	1/1	Pain	Ulcerated lesion Swelling Trismus	Single lytic	CT MRI	Yes
Ramaiah et al. ¹	Case report	1/1	Pain	Swelling in the maxilla tooth mobility	Punch-out	Panoramic radiograph CT	Yes
Jain et al. ⁴	Case report	1/1	None	Gingival swelling and tooth mobility	None	Skull radiograph	Yes
Kasamatsu et al. ³³	Case report	1/1	None	Swelling in the maxilla Tooth mobility	Single lytic with resorption of the floor of the maxillary Sinus	Panoramic radiograph CT MRI	Yes
Sreeja et al. ³²	Case report	1/1	Pain	Swelling in the mandible Amyloidosis	Multiple lesions punch-out	Skull radiograph	No
Fregnani et al. ³⁴	Case report	1/1	Trismus Paresthesia	Swelling in the mandible	Single lytic in the right mandibular ramus	Panoramic radiograph	Yes

^a Patients may present more than one oral manifestation.

MM: multiple myeloma; CT: Computed tomography; CBCT: cone beam computed tomography; MRI: Magnetic resonance imaging; NS: not specified.

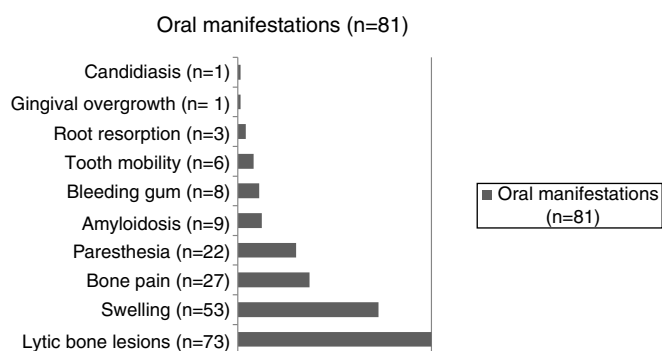


Figure 2 – Oral manifestations reported from the 81 individuals with multiple myeloma.

presented as the first sign of MM, and contributed to the diagnosis of the disease. The other studies showed oral signs or symptoms affecting individuals already diagnosed with MM. Eighty-one patients were reported with oral manifestations of MM. The most common clinical characteristics were swelling (65.4%), bone pain (33.3%), paresthesia (27.1%), amyloidosis lesions (11.1%), bleeding gums (9.8%), tooth mobility (6.1%), root resorption (3.7%), gingival swelling (1.2%) and candidiasis (1.2%) (Figure 2).

The majority of the patients ($n = 73$ –90.1%) exhibited bone lesions in the imaging exams of the jaws. From these, 53 cases were associated with clinical swelling. Table 1 shows the type of image used in each study and the reported findings. The typical pattern of reported lesions were plasmacytomas in 65 cases (80.2%) and “punched-out” lesions in eight cases (9.8%).

Discussion

The present study is a literature review focused on the oral manifestations of patients with MM with swelling being the most common. Osteolytic lesions of plasmacytomas were the most frequently reported radiographic signs of MM of the jaws.

Bone lesions are important features in the diagnosis of MM, and the most common radiographic manifestation (90.1%) reported in the papers that make up this review. Osteolytic bone lesions are the hallmark of MM and occur in the bone marrow microenvironment due to an interaction between tumor cells and stromal cells mainly related to an imbalance between osteoclasts, osteoblasts and soluble factors such as cytokines (e.g. interleukin 6), the receptor activator of NF- κ B ligand (RANKL) and its antagonist osteoprotegerin (OPG).²⁹ Recent data support the pathogenesis of MM lytic lesions as the result of increased cellular osteoclast activity (in number and function), and also the inhibition of new bone formation by the lack of osteoblast activity.²⁹

The majority of the studies reported bone lesions represented by plasmacytomas, but there were reports of “punched-out” lesions in seven cases.^{1,5,9,11,16,19} The bone lesions were more frequently reported in the mandible than in the maxilla, even though there is less hematopoietic bone marrow in the mandible.¹ These lesions were associated to bone pain in almost half of the reported cases. Many other conditions may result in complaints of bone pain, such

as osteomyelitis, osteoporosis, osteochondroma and bone metastasis of solid organ neoplasms. In the jaws, the most common cause for pain in the general population is odontogenic infection and thus, the differential diagnosis with this condition is of extreme importance. Moreover, oral pain, root resorption, and tooth mobility are conditions that may be eventually observed in association with other important bone diseases of the jaws.³⁰

Panoramic radiography is the imaging exam used in most of the papers included in this review, but other imaging exams such as computed tomography, intraoral radiographs, conventional craniofacial radiographs and magnetic resonance imaging were also reported. The panoramic radiograph is a common method for screening bone alterations of the jaws, but computed tomography has some advantages over radiographic examinations because of its tri-dimensional aspect and more accurate differentiation of tissue types, without superimposed overlying anatomy and no secondary and diffuse radiation degradation.

Most of the reported bone lesions were associated to clinical swelling,^{1,8,9,12,13,15–26,31–34} which may be explained by tumor expansion with neoplastic plasma cell activity in the bone.¹⁵ It may be assumed that swelling is a late stage of jaw lesions, after the tumor has expanded. Since more cone beam computed tomography images are being performed for dental treatment nowadays, it is possible that early lesions of MM will be detected.

Hemorrhagic episodes are observed in 15–30% of MM patients.³⁵ In the present review, bleeding gums were reported in nearly 10% of the reported cases. Thrombocytopenia can cause major bleeding, but there may also be local causes for bleeding such as periodontal disease.

MM is a hematologic malignancy characterized by the proliferation of clonal plasma cells in the bone marrow and secretion of a monoclonal protein (M-ptn) in the serum and/or urine.⁴ Commonly, tumoral cells secrete intact monoclonal immunoglobulin (heavy and light chains) with the most common isotypes involved in MM being immunoglobulin (Ig)G, IgA and light chains kappa or lambda.⁷ Besides myeloma, other monoclonal gammopathies and intermediary pre-malignant states, such as MGUS, smoldering myeloma (SMM), light chain amyloidosis and Waldenstrom macroglobulinemia, represent distinct entities with diagnostic criteria defined by the International Myeloma Working Group (IMWG).² The most prevalent of the gammopathies is MGUS, affecting about 3% of the over 50-year-old population. In spite of this, long-term follow up studies have shown that only one-third of the patients will progress to MM, amyloidosis, Waldenstrom macroglobulinemia or other lymphoproliferative disorders in 30 years.³⁶

Primary amyloidosis is a distinct entity characterized by a fibrillar ultrastructure deposit in target tissues (e.g. heart, kidney, nerves, liver, mucosa and gut) which may represent a single entity or, in nearly 10% of the cases, it may be part of a syndrome, overlapping MM.¹ Oral manifestations have been reported to affect one third of the patients with amyloidosis.³ In the cases reported by the studies of this review, amyloidosis was present in 11.1% of the MM cases. When an amyloid deposit is in the tongue it may result in macroglossia.³⁷ The enlarged tongue caused by amyloid

deposits may put pressure on the teeth, resulting in indentations on the borders of the tongue and open bite marks. If the tongue becomes too big to fit inside the mouth, it may become dehydrated, and present ulcerations with secondary infection. In cases of severe macroglossia, airway obstruction may occur.³⁰ Neurological complications may also occur due to amyloid infiltration of the nerves.^{37–39}

Most of the oral conditions found in patients with MM are not specific, so the differential diagnosis with other oral conditions and with manifestations of systemic diseases is important. Other oral conditions that have been reported in these patients are less frequently described and may not be directly associated to MM. Once the diagnoses of oral lesions are clarified, patients are referred to the proper specialist for further investigation and management of the condition.

In many studies, oral conditions were the first detected sign of MM.^{1,4–6,13,14,16,19,21–25,33,34,40–43} In others studies, oral manifestations of MM were detected during the patient's follow up and dentists were able to participate in the diagnosis of the oral condition.^{3,7,10,11,17,18,20,26,27,31,32,37,44,45} These patients need to be followed by a multidisciplinary team, who may improve their quality of life. Besides contributing to the diagnosis, dentists in the team need to take care of the dental health to prevent further complications, especially in patients who are candidates for antiresorptive therapy.

Some limitations were found during the review process. After applying study criteria, there were only case reports and case series in this review. Thus the incidence and prevalence of the oral manifestation could not be estimated. The absence of longitudinal and epidemiological studies on oral features of MM hampers the development of a meta-analysis. Future cross-sectional and longitudinal studies should be carried out to observe the prevalence and incidence of oral manifestations of MM, as well as the relationship of these findings with the prognosis of the condition.

The second limitation of this study is related to the imaging exams. Imaging was poorly described in many studies, and no description was available in some. Another difficulty was to compare the different types of imaging exams used, as recent studies used computed tomography scans, while in the past only radiographic examinations were used.

MM develops mainly in individuals aged 50–80 years.²¹ Thus, it is important that dentists are aware of clinical and imaging changes suggestive of MM lesions in patients of this age group. Dentists should be encouraged to detect oral manifestations of MM in routine examinations early. In this way, they will be contributing to increased survival and better prognosis.⁵

Conclusions

Swelling was the most common oral manifestation of MM and osteolytic lesions of the jaws were the most common radiographic sign. Dentists should be aware of the clinical and imaging signs of MM in the jaws, so that early diagnosis of oral lesions can be reached and patients referred for treatment.

Acknowledgements

This research was supported by Fundação de Amparo à Pesquisa do Estado do Rio de Janeiro (FAPERJ) JCNE E-26/103.046/2012, grants to Dr. Sandra R. Torres.

REFERENCES

1. Ramaiah KK, Joshi V, Thayi SR, Sathyanarayana P, Patil P, Ahmed Z. Multiple myeloma presenting with a maxillary lesion as the first sign. *Imag Sci Dent*. 2015;45(1):55–60.
2. Rajkumar SV, Dimopoulos MA, Palumbo A, Blade J, Merlini G, Mateos MV, et al., International Myeloma Working Group. Update criteria for the diagnosis of multiple myeloma. *Lancet Oncol*. 2014;15(12):e538–48.
3. Talamo G, Farooq U, Zangari M, Liao J, Dolloff NG, Loughran TP Jr, et al. Beyond the CRAB symptoms: a study of presenting clinical manifestations of multiple myeloma. *Clin Lymphoma Myeloma Leuk*. 2010;10(6):464–8.
4. Jain S, Kaur H, Kansal G, Gupta P. Multiple myeloma presenting as gingival hyperplasia. *J Indian Soc Periodontol*. 2013;17(3):391–3.
5. Lee SH, Huang JJ, Pan WL, Chan CP. Gingival mass as the primary manifestation of multiple myeloma: report of two cases. *Oral Surg Oral Med Oral Pathol Oral Radiol Endod*. 1996;82(1):75–9.
6. Zhao XJ, Sun J, Wang YD, Wuang L. Maxillary pain is the first indication of the presence of multiple myeloma: a case report. *Mol Clin Oncol*. 2014;2(1):59–64.
7. Witt C, Borges AC, Klein K, Neumann HJ. Radiographic manifestations of multiple myeloma in the mandible: a retrospective study of 77 patients. *J Oral Maxillofac Surg*. 1997;55(5):450–3.
8. Barr GS, Zweig B, Itkin AB. Intraoral corroboration of systemic plasma-cell myeloma. Abbreviated case report. *Oral Surg Oral Med Oral Pathol*. 1976;42(1):22–5.
9. Yoshimura Y, Takada K, Kawai N, Hasegawa K, Ishikawa T. Two cases of plasmacytoma in the oral cavity. *Int J Oral Surg*. 1976;5(2):82–91.
10. Kraut RA, Buhler JE, LaRue JR, Acevedo A. Amyloidosis associated with multiple myeloma. *Oral Surg Oral Med Oral Pathol*. 1977;43(1):63–8.
11. Epstein JB, Voss NJ, Stevenson-Moore P. Maxillofacial manifestations of multiple myeloma. *Oral Surg Oral Med Oral Pathol*. 1984;57(3):267–71.
12. Lambertenghi-Deliliers G, Bruno E, Cortelezzi A, Fumagalli L, Morosini A. Incidence of jaw lesions in 193 patients with multiple myeloma. *Oral Surg Oral Med Oral Pathol*. 1988;65(5):533–7.
13. Tamir R, Pick A, Calderon S. Plasmacytoma of the mandible: a primary presentation of multiple myeloma. *J Oral Maxillofac Surg*. 1992;50(4):408–13.
14. Furutani M, Ohnishi M, Tanaka Y. Mandibular involvement in patients with multiple myeloma. *J Oral Maxillofac Surg*. 1994;52(1):23–5.
15. Ho CL, Chen YC, Yiang YT, Kao WY, Chao TY. Mandibular mass as the presenting manifestation of IgM myeloma in a 22-year-old man. *Ann Hematol*. 1999;78(2):93–5.
16. Mozaffari E, Mupparapu M, Otis L. Undiagnosed multiple myeloma causing extensive dental bleeding: report of a case and review. *Oral Surg Oral Med Oral Pathol Oral Radiol Endod*. 2002;94(4):448–53.
17. Anacak Y, Kamer S, Donmez A, Haydaroglu A. Destruction of molar roots by metastasis of multiple myeloma. *Br J Oral Maxillofac Surg*. 2002;40(6):515.

18. Lae ME, Vencio EF, Inwards CY, Unni KK, Nascimento AG. Myeloma of the jaw bones: a clinicopathologic study of 33 cases. *Head Neck*. 2003;25(5):373–81.
19. Baykul T, Aydin U, OCarroll MK. Unusual combination of presenting features in multiple myeloma. *Dentomaxillofac Radiol*. 2004;33(6):413–9.
20. Owotade F, Ugboko V, Ajike S, Salawu L, Amusa Y, Omole M. Head and neck manifestations of myeloma in Nigerians. *Int J Oral Maxillofac Surg*. 2005;34(7):761–5.
21. Pinto LS, Campagnoli EB, Leon JE, Lopes MA, Jorge J. Maxillary lesion presenting as a first sign of multiple myeloma: case report. *Med Oral Patol Oral Cir Bucal*. 2007;12(5):344–7.
22. Segundo AV, Falcão MF, Correia-Lins Filho R, Soares MS, López J, Küstner EC. Multiple Myeloma with primary manifestation in the mandible: a case report. *Med Oral Patol Oral Cir Bucal*. 2008;13(4):232–4.
23. Shah A, Ali A, Latoo S, Ahmad I. Multiple Myeloma presenting as Gingival mass. *J Maxillofac Oral Surg*. 2010;9(2):209–12.
24. Ghosh S, Wadhwa P, Kumar A, Pai KM, Seshadri S, Manohar C. Abnormal radiological features in a multiple myeloma patient: a case report and radiological review of myelomas. *Dentomaxillofac Radiol*. 2011;40(8):513–8.
25. Vinayachandran D, Sankarapandian S. Multiple osteolytic lesions. *J Clin Imaging Sci*. 2013;3 Suppl. 1:6.
26. Cardoso RC, Gerngross PJ, Hofstede TM, Weber DM, Chambers MS. The multiple oral presentations of multiple myeloma. *Support Care Cancer*. 2014;22(1):259–67.
27. Troeltzsch M, Oduncu F, Mayr D, Ehrenfeld M, Pautke C, Otto S. Root resorption caused by jaw infiltration of multiple myeloma: report of a case and literature review. *J Endod*. 2014;40(8):1260–4.
28. Roodman GD. Skeletal imaging and management of bone disease. *Hematol Am Soc Hematol Educ Program*. 2008:313–9.
29. Hungria VT. Doença óssea em Mieloma Múltiplo [Bone disease in Multiple Myeloma]. *Rev Bras Hematol Hemoter*. 2007;29(1):60–6.
30. Neville BW, Damm DD, Allen CM, Bouquot JE. *Patologia oral e maxilofacial*. Trad. 3ª ed. Rio de Janeiro: Elsevier; 2009. p. 606–825.
31. Gray ST, Antunovic DM, White AE. Non secretory multiple myeloma involving the maxilla: report of a case with update of biology and new approaches to management. *Oral Oncol*. 1997;33(2):136–40.
32. Sreeja C, Vijayabanu B, Vijayalakshmi D, Devi M, Ramakrishnan K, Dhivya K. Multiple myeloma involving mandible: in an elderly female. *J Pharm Bioallied Sci*. 2015;7(2):763–5.
33. Kasamatsu A, Kimura Y, Tsujimura H, Kanazawa H, Koide N, Miyamoto I, et al. Maxillary swelling as the first evidence of multiple myeloma. *Case Reports in Dentistry*, vol. 2015. Hindawi Publishing Corporation; 2015, 5 pp.
34. Fregnani ER, Leite AA, Parahyba CJ, Nesrallah ACA, Ramos-Perez FMM, Cruz Perez DEC. Mandibular destructive radiolucent lesion: the first sign of multiple myeloma. *J Clin Exp Dent*. 2016;8(4):e465–8.
35. Kaushansky K, Williams WJ. *Williams hematology*. 9ª ed. New York: McGraw-Hill Medical; 2015, 2528 pp.
36. Faria RM, Silva RO. Gamopatias monoclonais – critérios diagnósticos e diagnósticos diferenciais. *Rev Bras Hematol Hemoter*. 2007;29(1):17–22.
37. Reinish EI, Raviv M, Srolowitz H, Gornitsky M. Tongue, primary amyloidosis, and multiple myeloma. *Oral Surg Oral Med Oral Pathol*. 1994;77(2):121–5.
38. Desport E, Bridoux F, Sirac C, Sébastien Delbes, Sébastien Bender, Béatrice Fernandez, et al. AL amyloidosis. *Orphanet J Rare Dis*. 2012;7:54.
39. Danette T, Sally Z. Bell Palsy. Medscape [internet]. Available from: emedicine.medscape.com/article/1146903-overview [cited 08.06.16].
40. Flick WG, Lawrence FR. Oral amyloidosis as initial symptom of multiple myeloma. A case report. *Oral Surg Oral Med Oral Pathol*. 1980;49(1):18–20.
41. Babajews A. Occult multiple myeloma associated with amyloid of the tongue. *Br J Oral Maxillofac Surg*. 1985;23(4):298–303.
42. Raubenheimer EJ, Dauth J, Coning JP. Short communications & case reports Multiple myeloma presenting with extensive oral and perioral amyloidosis. *Oral Surg Oral Med Oral Pathol*. 1986;61(5):492–7.
43. Vučićević-Boras V, Alajbeg I, Brozovic S, Mravak-Stipetic M. Burning mouth syndrome as the initial sign of multiple myeloma. *Oral Oncol Extra*. 2004;40(1):13–5.
44. Salisbury PL, Jacoway JR. Oral amyloidosis: a late complication of multiple myeloma. *Oral Surg Oral Med Oral Pathol*. 1983;56:48–50.
45. Jacobs P, Sellars S, King HS. Massive macroglossia, amyloidosis and myeloma. *Postgrad Med J*. 1988;64(755):696–8.