

sensation of acute myelomonocytic leukaemia and multiple myeloma. *Acta Haematol* 1982;68(02):153–156 (3) Annino L, Martino P, Barsotti P, Serra P, MARinozzi V, Mandelli F. Multiple myeloma and acute myelomonocytic leukemia: simultaneous occurrence without previous chemotherapy. *Acta Haematol* 1980;64:195–200

Table 1 – Laboratory and bone marrow biopsy findings of the patient at the time of diagnosis

Laboratory tests	Results	Normal Value
Hemoglobin	8,00 g/dL	12,1 - 16,6
Total leukocyte count	$2,51 \times 10^3/\mu\text{L}$	3,46 - 10,04
Platelets	$76 \times 10^3/\mu\text{L}$	172-380
Creatinine	0,86 mg/dL	0,7 - 1,2
Serum immunoglobulin G	57,82 g/L	7-16
β -2 microglobulin	3,56 mg/dl	-
Serum kappa free light chain	243	17-37
Serum lambda free light chain	10,8	9-21
Bone marrow plasma cell percentage	%35-40	

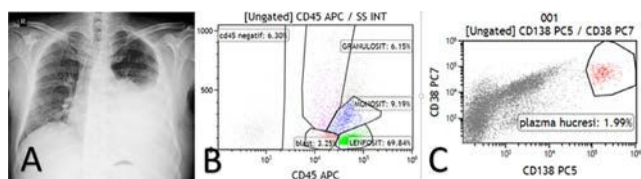


Figure 1: (A) Chest X-ray showed pleural effusion. (B) Pleural fluid was positive for myeloid blasts. (C) Plasma cell percentage of pleural fluid.

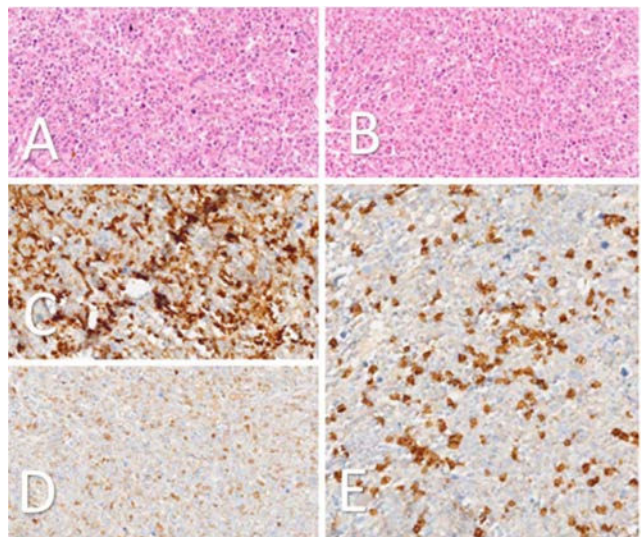


Figure 2: (A) Bone marrow biopsy, H & E stain $\times 40$. The bone marrow is hypercellular. (B) Bone marrow biopsy, H & E stain $\times 40$, The number of normal hematopoietic elements is markedly increased, the infiltrate consists of plasma cells and blasts. (C) Approximately 40% CD34 staining in the bone marrow parenchyma. (D) CD117 staining cells are 18% of the

marrow. (E) Number of cells stained with CD138, 18% of parenchyma.

<https://doi.org/10.1016/j.htct.2024.11.009>

OP 09

CASE REPORT: SIMULTANEOUS OCCURRENCE OF PLASMA AND B CELL MALIGNANCY

Nigar Abdullayeva^{1,*}, Damla Cagla Patr¹, Selin Kır¹, Ali Yılmaz¹, Derya Demir², Mehmet Soylu³, Mahmut Töbü¹

¹ Ege University Faculty of Medicine Department of Hematology

² Ege University Faculty of Medicine Department of Pathology

³ Ege University Faculty of Medicine Department of Microbiology

Objective: Multiple myeloma (MM) and chronic lymphocytic leukemia (CLL) are two distinct hematological malignancies thought to arise at different stages of the B cell maturation pathway. Here, we aimed to present our approach to such a patient. **Case report:** A 59-year-old male patient was examined for hematuria in 2019, lymphocytosis was detected, and flow cytometry (FC) was performed. The result was found to be compatible with CLL. The patient was evaluated as Binet A, Rai 0 at the diagnosis, and was followed without treatment. In the fourth year of treatment-free follow-up, the patient developed severe B symptoms and widespread lymphadenopathies (LAP), splenomegaly (size 15.5 cm) on imaging, and shortened lymphocyte doubling time, so bone marrow aspiration biopsy (BMAB), FC and cytogenetic tests were performed. The patient had a CLL immunophenotype score of 1 in flow cytometry, and cytogenetics showed negative 17p del and TP53 mutations. In BMAB, 80% atypical morphology and immunohistochemical (IHI) examination showed small lymphoid cells with CD19(+), CD20(+), CD23(+), and CD5(+) staining. The patient was evaluated as Binet B, Rai 2, and got 6 cycles of Chemoimmunotherapy (Rituximab, Fludarabine, Cyclophosphamide). After treatment, B's symptoms regressed, and LAP and splenomegaly returned to normal. The patient developed neutropenia requiring granulocyte colony-stimulating factor (G-CSF) during follow-up, therefore, the patient underwent repeat BMAB. In the result, plasma cells with intense kappa positive staining were observed, and in the IHI examination, the CD38 and 138 positivity rates were evaluated as 20%. The patient, who did not have hypercalcemia, renal dysfunction, anemia, bone lesions, and extramedullary involvement, was assessed as MGUS, neutropenia resolved spontaneously during follow-up, and it was decided to follow the patient at three-month intervals without treatment. **Conclusion:** MM and CLL were rare in the same patient, and there is limited information regarding clinical outcomes and management. The clonal relationship between them is controversial.

<https://doi.org/10.1016/j.htct.2024.11.010>