

OP18

Peripheral T-cell Lymphoma with Jaundice: Insights from a Complex Case

Candas MUMCU¹, Bengisu Ece DUMAN¹,
Berra Nur ISCI¹, Emre BAL¹,
Irem KABALCI KADIOGLU¹, Bulut SAT¹,
Meryem SENER², Hayriye TEZCAN³,
Arbil ACIKALIN³, Birol GUVENC²

¹ Cukurova University, Department of Internal Medicine, Adana, Turkey

² Cukurova University, Department of Internal Medicine, Department of Hematology, Adana, Turkey

³ Cukurova University, Department of Pathology, Adana, Turkey

CASE: Peripheral T-cell lymphomas (PTCLs) are a heterogeneous group of aggressive non-Hodgkin lymphomas with a rare occurrence, representing less than 15% of all adult non-Hodgkin lymphomas. The diagnosis and treatment of PTCLs pose significant challenges due to their diverse presentations and the aggressive nature of the disease. This case report discusses a 58-year-old male with a long-standing history of diabetes mellitus and previous bypass surgery, who presented with jaundice, hepatosplenomegaly, and ascites. Laboratory findings showed anemia, elevated liver enzymes, and hyponatremia. Imaging and biopsy results revealed nodular lung lesions, hepatosplenomegaly, liver mass lesions, bile duct dilatation, abdominopelvic lymphadenopathies, and T-cell lymphoma infiltration. The patient's treatment protocol included the CHOEP + BV regimen, alongside interventions for hyperbilirubinemia and renal failure. This case underscores the atypical presentation of PTCL with jaundice and the complexities involved in diagnosing and managing such cases, highlighting the need for a thorough and multidisciplinary approach.

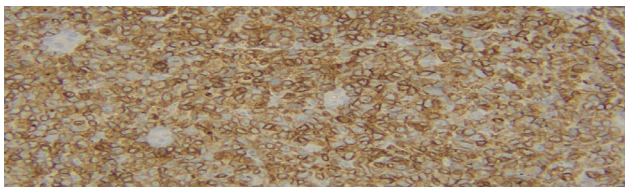


Image 1. Microscopic image of a biopsy taken from the liver (CD3 staining).

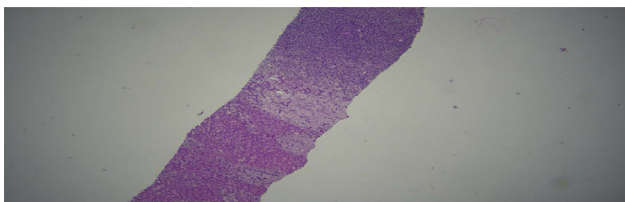


Image 2. Microscopic image of a biopsy taken from the liver (with normal liver tissue) (H&E staining).

<https://doi.org/10.1016/j.htct.2024.04.020>

OP19

Two Follicular Dendritic Cell Sarcoma (FDCS) patients treated with Chemoimmunotherapy

Berksoy Sahin, Birol Guvenc

Cukurova University, Medical Faculty Depts of
Medical Oncology and Hematology

Here we report 2 patients presenting with bulky lymphadenopathy in the abdominopelvic region. The first patient was a 64 yr old man and a lymph node biopsy from inguinal region revealed a CD23-positive, CD20-negative, CXCL13-positive and Ki67 40% positive follicular dendritic cell sarcoma. The patient received 6 courses of chemotherapy combined with PD-1 MoAb (pembrolizumab. A gemcitabine plus docetaxel regimen (GemDoc) combined with 200 mg pembrolizumab. At the end of 6 courses, PET/CT presented a metabolic CR. We continue the same cheoimmunotherapy regimen as maintenance treatment. The second patient is a 44 year old man who has an intraabdominal bulky tumor and multiple hepatic metastasis. Core biopsies from liver lesions and intra-abdominal mass revealed FDCS. The patient took the first course of the same regimen of chemoimmunotherapy composed of a GemDoc+pembrolizumab and felt comfortable because of the decrease in tumor sizes. A very rare entity, FDCS has no a standart treatment, yet. We combine a second line sarcoma regimen (GemDoc) with Anti-PD1 Ab, pembrolizumab as induction systemic treatment and followed by a maintenance Pembrolizumab. This chemoimmunotherapy regimen suggest that it will work in FDCS patients who have intermediate PD-L1 expression in tumor cells.

<https://doi.org/10.1016/j.htct.2024.04.021>

OP20

Neoadjuvant chemoimmunotherapy for a patient with micro-stallate instabile gastric cancer resulted a pathological complete response

Berksoy Sahin, Birol Guvenc

Cukurova University, Medical Faculty Depts of
Medical Oncology and Hematology

Here we presented a 44 yr old male patient with an abdominal pain who had a distal gastric adenocarcinoma in his endoscopic biopsy. The pathology reported a chromogranine negative, CK20-positive, PD-L1 5% positive adenocarcinoma with MLH1 (-)and PMS-2(-) MSI status. PET/CT showed enlarged gastric wall (SUVmax 23.99) and enlarged perigastric lymphadenopathy (SUVmax 22.03) and no distant metastasis. The patient received 4 courses of Nivolumab plus FLOT-4 chemoimmunotherapy in neoadjuvant setting. He experienced Grade 2 myelotoxicity and 2 packages of red blood were transfused. Following 4 courses of chemoimmunotherapy a total gastrectomy was performed and the pathology reported no evidence of tumor in the stomach and also perigastric lymphnodes revealing a pathological complete response. There has

been no standart treatment for MSI-high gastric cancer, yet. Very few phase I-II studies wth limited number of patients suggest an immunotherapy-based treatment. Here we report a combination regimen of original FLOT-4 chemotherapy with an PD-L1 Ab (nivolumab) that resulted a pCR in the

neoadjuvant setting. Four courses of the same chemotherapy was planned in the adjuvant setting.

<https://doi.org/10.1016/j.htct.2024.04.022>