

POSTER PRESENTATIONS

ADULT HEMATOLOGY ABSTRACT CATEGORIES

CHRONIC LEUKEMIA

PP 01

MOLECULAR ASPECTS IN CHRONIC LYMPHOCYTIC LEUKEMIA PATIENTS WITH AUTOIMMUNE CYTOPENIAS: SINGLE CENTER EXPERIENCE

Sanja Trajkova, Nevenka Ridova,
Marija Popova Labacevska,
Aleksandra Pivkova Veljanovska,
Simona Stojanovska, Dushko Dukovski,
Milche Cvetanoski, Lazar Cadievski,
Bozidar Kocoski, Irina Panovska Stavridis

University St. Cyril and Methodius, Skopje,
Macedonia University Clinic for Hematology, Skopje,
Macedonia

Objective: Autoimmune cytopenia's, particularly autoimmune hemolytic anemia (AIHA) and immune thrombocytopenia (ITP), complicate up to 25% of chronic lymphocytic leukemia (CLL) patients. Their occurrence correlates with a more aggressive disease. AIHA and ITP are more frequently found in patients with unfavorable biological risk factors for CLL. B lymphocytes at CLL are responsible of pathogenic mechanisms, involving aberrant antigen presentation and cytokine production. The aim of this study was evaluation of autoimmune cytopenia's in chronic lymphocytic leukemia patients from Republic of North Macedonia in correlation with genetic structure of pathologic B lymphocyte. **Methodology:** This is a retrospective study of patients with CLL, diagnosed and followed in the period between January 2011 and January 2021. Individual data from 100 treatment naïve CLL patients were analyzed, and mutational status and configuration of IGHV-IGHD-IGHJ rearrangements and genetics were analyzed using reverse transcriptase– polymerase chain reaction (RT-PCR) and sequencing methodology at the center for bimolecular pharmaceutical analyses, faculty of pharmacy, Skopje, Republic of North Macedonia. **Results:** Our 2531-1379/

evaluation have shown that 10% of CLL patients had AIHA and 4% had ITP. Most of the patients with autoimmune cytopenias had unmutated IGHV genes. The most frequently expressed IGHV subgroup was IGHV1-69 (71%), followed by IGHV3-13 and IGHV4-4 (14%). The genetic results presented unfavorable cytogenetics with 11q deletions and NOTCH1 mutation. **Conclusion:** The results of our study are consistent with published studies with specific molecular signature.

<https://doi.org/10.1016/j.htct.2022.09.1236>

CHRONIC MYELOPROLIFERATIVE DISEASES

PP02

FOLLOW-UP OF CHRONIC MYELOID LEUKEMIA PATIENTS WHOSE TYROSINE KINASE TREATMENT WAS STOPPED: CASE SERIES

Kemal Fidan ^{1,2}, Ali Unal ^{1,2}

¹ Erciyes University

² Erciyes University Faculty of Medicine,
Department of Internal Medicine, Department of
Hematology

Introduction: Chronic Myeloid Leukemia (CML) is a myeloproliferative disease characterized by the formation of the BCR ABL1 fusion protein with translocation t(9;22) (Philadelphia chromosome-Ph). With recent studies, it has been understood that the treatment of adult chronic phase CML patients who have achieved a deep molecular response with the use of TKI and can maintain this response for a long time can be safely terminated; It has been observed that it is possible for patients to remain in long-term molecular remission without the use of TKI. Based on these studies, we will try to present the follow-up processes of chronic phase CML patients, who were followed up in our clinic and whose TKI treatment was stopped. **Case reports:** First case; A 69-year-old female patient was diagnosed with Ph positive chronic phase CML in 2008. The imatinib treatment of the patient, who had been using imatinib for about 13 years and was bcr-abl negative for the

last 3 years, was discontinued in December 2021. In the 2nd and 4th months, the requested bcr-abl was negative. Second case; a 42-year-old male patient was diagnosed with Ph-positive chronic phase CML in 2006. The patient, who had been using imatinib for about 16 years and was bcr-abl negative for the last 3 years, was discontinued in April 2022. bcr-abl came back negative. Third case; a 42-year-old female patient was diagnosed with Ph positive (IS: 31,824) chronic phase CML in 2019. He received Nilotinib and Dasatinib treatment after he had an allergic skin reaction using imatinib for about 2 years. The patient had drug intolerance and was bcr-abl negative for about 2 years, and the treatment was stopped. The 1-month follow-up was negative for bcr-abl. Fourth case; Imatinib was started in a 50-year-old female patient with the diagnosis of Ph-positive chronic phase CML in 2012. Due to imatinib intolerance, the treatment of the patient who was using nilotinib and was bcr-abl negative for the last 3 years was discontinued in February 2021. The bcr-abl negativity continues in the follow-ups. Fifth case: A 58-year-old female patient was diagnosed with Ph-positive chronic phase CML in 2013. The imatinib treatment of the patient, who has been using imatinib for about 8 years and has been negative for bcr-abl for the last 3 years, was discontinued in November 2021. The bcr-abl negativity continues in the follow-ups. **Conclusion:** STIM 1 (Stop Imatinib) study is the first multicenter, non-randomised, prospective study on TKI termination. Then, TWISTER, A-STIM, ENEST, STOP2GTKI, EURO SKI studies were carried out. In these studies, TKI treatment was discontinued in patients who used TKI for at least 3 years and had a major molecular response for the last 2 years. Remission was achieved in approximately 50% of the patients who were followed up without medication. In our study; The treatment of patients who had been using TKI for 5 years and had a major molecular response for about 2 years was stopped. The follow-up of the patients (minimum: 1 month, maximum: 15 months) continues, and all of them are in remission.

<https://doi.org/10.1016/j.htct.2022.09.1237>

PP 03

TREATMENT-FREE REMISSION IN PATIENTS WITH CHRONIC MYELOID LEUKEMIA: MANAGEMENT APPROACHES

Vasile Musteata

State University of Medicine and Pharmacy
“N. Testemitanu”, Institute of Oncology

Objective: The study objective was to analyze the short- and long-term results of treatment discontinuation in patients with chronic myeloid leukemia (CML) and complete molecular response (CMR). **Methodology:** This prospective study enrolled 22 patients (pts) with chronic phase of CML, managed at the Oncologic Institute from Moldova between 2017–2022. The age range was 29–73 years. The male/female ratio was 1:1.2. The real-time quantitative PCR revealed the wide range of BCR-ABL p210 transcript: 21.84–100% IS. In 7 (31.8%) pts the rate of BCR-ABL p210-positive cells was less than 50%.

CMR was achieved in 15 (68.2%) pts after imatinib therapy and in 7 (31.8%) pts after the 2nd generation of TKIs. **Results:** The therapy with TKIs was stopped due to the different reasons in all patients after the CMR was obtained. Two (9.1%) pts stopped the TKIs treatment due to the pregnancy. The molecular relapse occurred in 6 (27.3%) pts, including one pregnant female. All relapsed pts had the initial BCR-ABL p210 transcript expression > 50%. The CMR span ranged between 2.5–26 months in relapsed pts. The range of BCR-ABL p210 transcript in the relapsed pts was 0.002–0.56%. These pts achieved the 2nd CMR after restarting TKIs treatment. All pts are alive, with the ECOG score of 0–1. **Conclusion:** TKIs discontinuation may be considered an option in CML patients with CMR, especially in those with the initially low BCR-ABL p210 transcript expression. The 2nd CMR may be obtained after restarting the TKIs treatment in pts with minor molecular relapse.

<https://doi.org/10.1016/j.htct.2022.09.1238>

COAGULATION DISEASES

PP 04

PHENOTYPE/ GENOTYPE SCREENING PATTERN OF HEMOPHILIA A AND B IN SAUDI ARAB

Tarek Owaidah¹, Salwa Bakr²,
Hala AbaAlkhail¹, Hazza Alzahrani¹,
Mahasen Saleh¹, Abdulrahman Almusa¹,
Nouf Al-Numair³, Haitham Khogeer¹,
Faisal Al-Allaf⁴

¹ Department of Pathology, King Faisal Specialist hospital and Research Center, Riyadh, Saudi Arabia

² Department of Clinical Pathology/Hematology, Faculty of Medicine, Fayoum University, Egypt

³ Saudi Human Genome Program, King Abdulaziz City for Science and Technology, Riyadh, Saudi Arabia

⁴ Department of Medical Genetics, Umm Al-Qura University Faculty of Medicine, Makkah, Saudi Arabia

Objective: Hemophilia A and B are X-linked recessive bleeding disorder caused by variants in the factor VIII (FVIII) and factor IX (FIX) genes. There is correlation between the type of mutation and clinical severity of these patients. Establishing national screening program for haemophilia patients is highly encouraged by the World Health Organization (WHO) and World Federation of Haemophilia (WFH). Hence we aimed to establish a genotypic data base for the nature of mutations present in Saudi population. **Case report:** This retrospective descriptive study on a cohort of 136 Saudi hemophilia A and B patients. **Methodology:** Molecular studies were performed to identify known and novel causative variants in hemophilia A and B families and correlated with some clinical features. **Results:** There were 129 male and 7 females with age ranged from 2 - 62 years old, 97 (71.3%) hemophilia A (HA) and 39

(28.7%) hemophilia B (HB). The clinical severity of hemophilia A ranged between mild (10, 10.3%), moderate (2, 2.1%) and severe (83, 85.6%), while for hemophilia B (mild 13 (33.3%), moderate 2 (5.1%) and severe 24 (61.5%) respectively. There were 76 (55.9%) had chronic joint disability. Factor inhibitors with different titers were detected in 24 (24.7%) of HA and only 2 (5.1%) of HB. Out of the whole cohort 136 had been tested for causative variants, 17 (12.5%) were positive for inv-22 and 4 (2.9%) for inv-1, while all negative HA were selected for analysis by next generation sequencing. We are reporting 3 cases of females with severe forms of hemophilia. We are reporting different mutations that was consistent in group of tested members of same family /trip. We confirmed as previously reported high frequency of inv 22 and we found 7 novel mutation out 12 detected variants for HA and one novel mutation out of 13 detected variants for HB. **Conclusion:** These results will enrich the spectrum of variants and enlarge the factor VIII and factor IX proteins database in the Saudi Arabian population. Establishing a molecular genetic based tests for fast, easy, and cost effective reliable mutation screening that can also be applied in the future for prenatal and pre-implantation genetic diagnosis.

<https://doi.org/10.1016/j.htct.2022.09.1239>

PP05

SERUM LEVEL OF VASCULAR CELL ADHESION MOLECULE AND P SELECTIN AS THROMBOPHILIC RISK FACTOR FOR EARLY VASCULAR ACCESS THROMBOTIC OCCLUSION IN HEMODIALYSIS PATIENTS

Mohamed Sherif, Amr Gawaly, Heba Murad, Mohamed Dawoud, Kamal Okasha

tanta university

Objective: Hemodialysis (HD) vascular access (VA) failure is the dominant cause of morbidity and the major cost of care for ESRD patients. The aim of the present work is to assess the serum level of vascular cell adhesion molecule and P-selectin in HD patients as markers for early thrombotic VA event. **Methodology:** 90 CKD patients divided into three groups: group I: 10 subjects apparently health, group II: 10 Patients with CKD stage IV-V on medical treatment and group III: 70 Patients with CKD stage V on HD with recent VA insertion divided into 2 subgroups: Subgroup III a: 57 patients with AV shunt and subgroup III b: 13 patients with permanent catheter. Laboratory investigations done (blood urea, serum creatinine, eGFR, CBC, PT, and INR), imaging and serum VCAM 1, P selectin before and 6 months after HD **Results:** There was positive connection between VCAM and P selectin and dialysis with statistics in form of p value (<0.001). Markers level pre dialysis and after 6 months of dialysis revealed that range of p selectin and VCAM1 level after 6 months are higher than pre dialysis level. **Conclusion:** Detection of elevated serum level of circulating sVCAM-1 and s P-selectin could be useful in the prediction of native AVF and

permanent catheter thrombosis in chronic HD patients. The association between sVCAM-1 and s P-selectin and thrombosis in HD patients increases the evidence of the role of adhesion molecules in VA thrombosis

<https://doi.org/10.1016/j.htct.2022.09.1240>

PP06

SUCCESSFUL MANAGEMENT OF SEVERE CONGENITAL FACTOR X DEFICIENCY DURING PREGNANCY AND LABOR WITH PCC IN TWO SISTERS

Alfadi Haroon¹, Riad Elfakih¹, Hazzaa Alzahrani¹

¹ Oncology Centre, King Faisal Specialist Hospital and Research Centre, Riyadh, KSA

Introduction: Factor X (FX) deficiency is an autosomal recessive disorder caused by quantitative or qualitative defects in the FX protein. FX deficiency has an estimated worldwide prevalence of one in 1000000. ⁽¹⁾ Pregnancy in women with congenital FX deficiency has been associated with adverse fetal outcomes (abortion and preterm labor) (2,11). We report two cases of successful pregnancy with factor X deficiency. **Case 1:** A 29-year-old woman with congenital factor X deficiency and prior abortion on prophylaxis PCC every 4 weeks. She was treated with PCC 25unit/kg twice weekly during the pregnancy course. At week 32 of pregnancy, she presented with labor pain. Lab showed PT 20.7 PTT 52.5 INR1.5 Fibrinogen 3.8 Hb13.8 platelet 195 WBCs 7.6 factor X 0.15. She was given PCC 25 units/kg until a level of 0.4 was achieved. She delivered a healthy, 1.9 kg baby by normal vaginal delivery. The estimated blood loss was 150 ml. She then received FX 15 units/kg for 3 days postpartum to maintain FX level >30% and INR <1.5. No episodes of abnormal bleeding were observed during pregnancy, labor or postpartum. **Case 2:** A 36-years-old woman with congenital factor X deficiency and two prior abortions, on prophylaxis PCC every 4 weeks. She received prophylaxis PCC 25units/kg twice weekly during the course of this pregnancy. At week 38 of pregnancy, she delivered a healthy 3.2 kg baby by cesarean section (CS) after failing labor induction. Lab showed PT 23.7 PTT 50.4 INR1.7 Fibrinogen 2.3 CBC was normal.FX 0.13. She was given PCC 25 units/kg until a level of 0.4 was achieved. The estimated blood loss was 500 ml. She then received FX 15 units/kg for 7 days postpartum to maintain FX level >30% and INR <1.5. She was discharged on tranexamic acid. No episodes of abnormal bleeding were observed during pregnancy CS or post-partum. **Discussion:** Although FX activity increases during normal pregnancy, levels usually remain insufficient for hemostasis at delivery in women with severe FXD (4,5,6). FX replacement therapy with PCC or FX concentrate may be required to treat or prevent bleeding in FXD. Therefore, a therapeutic dose of PCC 20–30 iu/kg is expected to increase plasma FX activity by 0.4–0.6 iu/ml. Further infusions at 1- to 2-d intervals may be required if sustained treatment is necessary ⁽³⁾. There are reports of FX replacement with PCC during pregnancy in women with previous adverse pregnancy outcomes (7,8) and FX

replacement during labor with PCC or FFP, but with different regimens⁽⁹⁾. Our patients were treated with PCC prophylaxis during pregnancy and 25 units/kg during labor. No bleeding nor thrombosis was seen in both cases. The British guidelines recommend PCC 20–40 iu/kg during the third trimester for women with history of bleeding and with FX activity <03 iu/ml with the goal of achieving FX activity >04 iu/ml. They also recommend, to consider further PCC 10–20 iu/kg once daily to maintain FX activity >03 iu/ml for at least 3 days post-partum.⁽¹⁰⁾ **Conclusion:** Prophylactic PCC resulted in excellent hemostasis in two of our patients, including one that delivered by C-section.

<https://doi.org/10.1016/j.htct.2022.09.1241>

LYMPHOMA

PP 07

PREVENTION CAN BE THE BEST TOOL FOR ADULT T-CELL LEUKEMIA. UPDATED T-CELL BRAZIL PROJECT

Carmino De Sousa¹, Carlos Chiattoni², Eliana Miranda¹, Yung Gonzaga³, Maria Dias⁴, Renata L R Baptista⁵, Davimar Borducchi⁶, Guilherme Duffles¹, Marcelo Bellesso⁷, Juliana Pereira⁸, Sergio Brasil⁹, Nelson S CASTRO¹⁰, Karin Z CECYN¹¹, Rony SCHAFFEL¹², Massimo Federico¹³

¹ University of Campinas – UNICAMP, Hematology and Hemotherapy Center, SP

² Samaritano Hospital – Higienópolis & Santa Casa Medical School of Sao Paulo

³ Cancer National Institute – INCA, RJ

⁴ Federal University of Bahia – UFBA

⁵ State University of Rio de Janeiro – UERJ & Instituto D'Or de Pesquisa e Ensino (IDOR), RJ

⁶ Medical School of ABC, Santo Andre, SP

⁷ HemoMed, Instituto de Ensino e Pesquisa – IEP, São Lucas, SP

⁸ Medicine School of University of São Paulo, SP

⁹ Santa Casa Medical School of Sao Paulo

¹⁰ Cancer Hospital Barretos, Hospital de Amor, SP

¹¹ Federal University of Sao Paulo - UNIFESP

¹² Federal University of Rio de Janeiro – UFRJ, Clementino Fraga Hospital, RJ

¹³ University of Modena and Reggio Emilia, Italy

Objective: T-cell Brazil project started in April 2017 an ambispective study focusing to collecting epidemiological and clinical data from the most frequent subtypes of PTCL, among them the ATL. As of July 2022 T-cell Brazil database contained 81 (16%) ATL out of 520 registered cases. Our goals are to describe demographic and clinical features, analyze the overall and progression-free survival (OS and PFS), and try to identify factors that could influence outcome. **Methodology:** Brazilian Registry using REDcap Platform by Vanderbilt realized descriptive and bivariate analyses, then it was applied Kaplan-Meier method and log-rank test to obtain survival

estimates, and besides that, it was used the Cox Regression to identify any factor that could influence the OS and PFS. **Results:** The median age was 52 years (24-91); 32 (39%) male; the majority of clinical subtypes were 52% lymphoma type; 81% received chemotherapy. The best response assessment after first-line treatment was: progression or no response in 31%; 26% complete response; 21% partial response, 21% not available (NA) due to death or on treatment; 34% of patients were alive and the 24-month OS and PFS was 33% and 21%, respectively. As predictors for PFS and OS were B symptom and elevated LDH values. **Conclusion:** This study, even recognizing a limited sample size, highlights the poor prognosis associated with ATL, mainly acute and lymphoma type, with high mortality rates. Hence, apparently, a good shot, it would be one of the bases for the prevention of ATL to establish a disease entity of “chronic active HTLV-1 infection” that defines high-risk carriers for ATL development, and then, enables preventive intervention.

<https://doi.org/10.1016/j.htct.2022.09.1242>

PP08

AN UNUSUAL OCULAR LYMPHOMA, PRIMARY INTRAVITREAL LYMPHOMA DIAGNOSED INCIDENTALLY

Nur Seda Ibili Cetinkaya¹, Simge Erdem¹, Nursema Deniz², Berna Basarir³, Halil Özgür Artunay³, Tarık Onur Tiryaki¹, Ali Emre Bardak², Hazel Taş², Meliha Nalcaci¹, Sevgi Kalayoglu Besisik¹

¹ Istanbul University Istanbul Faculty of Medicine, Department of Internal Medicine, Division of Hematology

² Istanbul University Istanbul Faculty of Medicine, Department of Internal Medicine

³ University of Health Science, Beyoglu Eye Training and Research Hospital

Objective: Ocular lymphoma involvement can be either secondary during systemic lymphoma or primary. Diagnosis can be troublesome due to insidious disease onset. Uveitis is the main differential diagnosis. The prognosis is poor. **Case report:** A 62-year-old male patient was evaluated during a periodical check-up for hypertensive retinopathy. The unexpected good vision quality with severe left vitreous infiltration and not associated macular edema contributed to malignancy suspicion. A diagnostic procedure was performed bilaterally. Both of the vitreal tissue revealed atypical lymphoid cells with B-Cell phenotype. Cranial MRI, PET-CT, and CSF analysis documented the case as primary vitreoretinal lymphoma (VRL). **Methodology:** First-line treatment was with intravitreal methotrexate (MTX). After 10 courses, high-dose cytarabine-based treatment was given as consolidation. Considering high recurrence rates, stem cells were mobilized and cryopreserved for future use for autologous stem cell transplantation (ASCT). **Results:** Follow-up was 3 monthly. After 10 months of remission period, retinal disease relapse was spotted. After 5 cycles bilateral intravitreal

MTX, disease progressed as leukemic invasion of left optic nerve. High dose chemotherapy followed by ASCT was performed. **Conclusion:** Diagnosis of IVL is challenging due to late onset macular edema. Related with high relapse rates with high mortality, high-dose chemotherapy is the recommended management type currently.

<https://doi.org/10.1016/j.htct.2022.09.1243>

PP09

THE RELATIONSHIP BETWEEN FERRITIN LEVEL AND THROMBOSIS IN PATIENTS WITH DIFFUSE LARGE B-CELL LYMPHOMA

Buğra Sağlam¹, Murat Albayrak²,
Abdulkerim Yıldız³, Pınar Tıplıoğlu⁴,
Mesut Tıplıoğlu⁴, Merih Reis Aras²,
Fatma Yılmaz², Hacer Berna Afacan Öztürk²

¹ sanlıurfa Mehmet Akif Inan Training and Research Hospitala

² University of Health Sciences Ankara Dışkapı Yıldırım Beyazıt Training and Research Hospital, Department of Hematology

³ Gaziantep Dr. Ersin Arslan Training Research Hospital, deartment of Hematology

⁴ Hitit university Erol Olçok Training and Research Hospital, Department of Hematology, Çorum

Objective: Cancer is a well-known condition associated with its treatment and follow-up and increases the risk of thrombosis. As with solid tumors, the risk of venous thromboembolism (VTE) is quite high in lymphomas, especially high-grade B-cell lymphomas. Diffuse large B-cell lymphoma (DLBCL) patients are the most important part of this group. The aim of our study is to determine the effect of ferritin level at the time of diagnosis on thrombosis in DLBCL patients. **Methodology:** In this retrospective study, 133 patients who applied to SBU Dışkapı Yıldırım Beyazıt Training and Research Hospital Hematology clinic and were diagnosed with DLBCL were included in this retrospective study. Demographic characteristics, disease-related findings, presence of central venous catheter and laboratory results of the patients were recorded. **Results:** The median age of the patients included in the study was 63.13±14.85 years. There were 67 female and 66 male patients, stage 1-2: 54 patients, stage 3-4: 79 patients at the time of diagnosis. Thrombosis was observed in 16 of the patients. Median ferritin levels were 357.42 ug/L and 253.07 ug/L, respectively, between the group with and without thrombosis (p:0.026). The ferritin value, which was examined for the presence of thrombosis, was determined as 227 ug/L as a result of the ROC analysis. In the logistic regression analysis, the risk of developing thrombosis was 6.1 times higher in those with a ferritin level ≥227 ug/L. **Conclusion:** Hyperferritinemia may be an independent risk factor for the development of thrombosis in DLBCL patients. In case of hyperferritinemia in patients, initiation of thromboprophylaxis may be an appropriate approach.

<https://doi.org/10.1016/j.htct.2022.09.1244>

PP 10

RITUXIMAB INDUCED LUNG DISEASE IN A MANTLE CELL LYMPHOMA PATIENT RECEIVING MAINTENANCE: CASE PRESENTATION

Aslı Öztürkmen, Eyyüp Akkaya, Eren Davulcu,
Emine Gültürk, Fehmi Hindilerden

University of Health Sciences Hamidiye School of
Medicine Bakırköy Dr. Sadi Konuk Training and
Research Hospital

Introduction: Rituximab-induced lung disease (R-ILD) is a rare entity that should be considered in patients treated with rituximab who present with dyspnea, fever, and cough but no clear evidence of infection. We describe the clinical presentation, management, and response to rechallenge in one mantle cell lymphoma patient who developed R-ILD during maintenance rituximab. **Case report Case:** 66 years old male with history of mantle cell lymphoma (MCL), who had been treated with RCHOP and underwent autologous stem cell transplantation (ASCT), was diagnosed with relapse 5 years after ASCT. Six courses of rituximab-bendamustine resulted in 2nd complete response and 2-monthly rituximab maintenance was initiated. 10 days after 3rd rituximab, he presented with a 1 week history of progressive exertional dyspnea and cough. He was tachypneic and hypoxemic. **Methodology:** Thorax HRCT showed peripheral bilateral patchy ground glass opacities and nodular opacities. Bronchoalveolar lavage identified no bacterial, viral or fungal pathogen. With presumptive diagnosis of late R-ILD, methylprednisolone (MP) 1 mg/kg/day was started. In absence of rapidly progressing respiratory failure and fever, the patient was evaluated as non severe R-ILD. Thus, rechallenge with rituximab is being considered due to the risk of relapse of MCL. **Results:** Discussion: Reported rate of possible R-ILD is <0.03% in over 540,000 patients. Pulmonary complications of rituximab are hypersensitivity pneumonitis, ARDS, interstitial pneumonitis, organizing pneumonia, pulmonary fibrosis, and alveolar haemorrhage. Symptoms of R-ILD are dyspnea, fever, and hypoxemia and HRCT findings include focal alveolar densities, ground glass opacities and alveolar opacification. Time to symptom onset ranges from 1 day to several weeks after 1st infusion with mean **Conclusion:** mean duration of 3 months. Our patient had received rituximab prior to relapse and developed R-ILD after 9 doses of rituximab for relapse, which is a rare finding. All other causes of potential lung injury had to be meticulously excluded. ILD is a rare but potentially fatal pulmonary toxicity due to rituximab. As the symptoms at presentation are nonspecific, physicians must maintain a high index of suspicion to recognize it early and initiate treatment to avoid severe morbidity and mortality.

<https://doi.org/10.1016/j.htct.2022.09.1245>

PP 11

THE DIVERSITY OF PRESENTATION AND MANAGEMENT OF SUBCUTANEOUS PANNICULITIS –LIKE T-CELL LYMPHOMA WITH ASSOCIATED HEMOPHAGOCYTIC SYNDROME - CASE SERIES ANALYSIS

Agnieszka Giza¹, Justyna Jedras¹, Maria Rozploch², Ewa Czepko³, Marcin Jonca⁴, Dagmara Zimowska-Curylo¹, Mateusz Wilk¹, Malgorzata Razny⁴, Walentyna Balwierz³, Tomasz Sacha¹

¹ Department of Hematology, Jagiellonian University Medical College, Krakow, Poland

² Student Scientific Group, Department of Dermatology, Jagiellonian University Medical College, Krakow, Poland

³ University Children's Hospital, Department of Pediatric Oncology and Hematology, Krakow, Poland

⁴ Rydygier's Specialistic Hospital, Department of Hematology, Krakow, Poland

Objective: Subcutaneous panniculitis-like T-cell lymphoma (SPTCL) is a rare hematological malignancy affecting subcutaneous adipose tissue, typically with no involvement of the lymph nodes. SPTCL is associated with the increased risk of the hemophagocytic syndrome (HPS), significantly affecting prognosis and overall survival. This study aimed to present different clinical characteristics, management strategies, and outcomes in three patients diagnosed with SPTCL. **Methodology:** A retrospective study of the three patients diagnosed with SPTCL admitted to Hematology Departments in Krakow was conducted. Collected data included patients' clinical characteristics and symptoms, laboratory testing, imaging tests, implemented treatment strategies and response assessment. **Results:** The analyzed patients (aged 15-35), presented lesions involving mainly skin in 2 patients, and mesenterium in one subject; HPS was confirmed in each case. The first line treatment consisted of HLH protocols followed by next line chemotherapies in two patients, and then with high dose therapy in one case. Cyclosporine A (CyA) was implemented in two patients, and in one case this was an initial choice. CR was achieved in 2 patients, including the subject treated with CyA from the beginning. **Conclusion:** This series shows a diversity of presentations and implemented management in three patients. Since SPTCL is an extremely rare condition with no standardized established therapy, choosing the optimal treatment approach is a relevant problem. The increasing data shows the effectiveness and safety of immunosuppressive treatment with CyA versus intensive chemotherapy and supports the application of CyA also in patients with developed HPS.

<https://doi.org/10.1016/j.htct.2022.09.1246>

PP12

RELAPSED MANTLE CELL LYMPHOMA WITH ISOLATED CENTRAL NERVOUS SYSTEM INVOLVEMENT THAT TREATED WITH IBRUTINIB; A CASE REPORT AND LITERATURE REVIEW

Pinar Tiglioglu¹, Salih Sertac Durusoy², Melis Mutlu², Mehmet Yilmaz²

¹ Dr. Ersin Arslan Education and Research Hospital Department of Hematology

² Sanko University School of Medicine Department of Internal Medicine/Hematology

Objective: Mantle cell lymphoma (MCL) is an aggressive B-cell lymphoma, constitutes 3-10% of all non-Hodgkin's lymphomas. MCL usually presents with generalized lymph node involvement. The prognosis is poor and incurable. Extranodal involvement is not uncommon, but central nervous system involvement is very rare. Herein, we present a case with isolated central nervous system relaps who achieved a complete response with ibrutinib treatment. **Case report:** 53yearold female patient diagnosed with MCL underwent autologous stemcelltransplantation after R-CHOPchemotherapy. While being followed up in complete remission, she presented with a complaint of headache. Parenchymal lesions in brain was observed in MRI.Cerebrospinal fluid flow cytometric and cytological examination revealed MCL-centralnervoussystem involvement. There was no finding in terms of systemic relaps.The patient was achieved complete response with ibrutinib and high dose methotrexate **Results:** Central nervous system involvement at the time of diagnosis in mantle cell lymphoma is very rare however it can be more common in relaps and generally is associated with advanced stage disease or is a part of systemic relaps. Our case is quite interesting as it presents with isolated central nervous system infiltration. In this case, our treatment choice was ibrutinib because of its satisfactory response rates and proven effectiveness on central nervous system. **Conclusion:** The patient is currently being followed up with a complete response. It should be underlined that even in patients followed up with complete remission, symptoms such as headache, which can sometimes be subjective, should be approached sensitively, and it should not be forgotten that they may indicate an unexpected involvement of the disease.

<https://doi.org/10.1016/j.htct.2022.09.1247>

PP13

IS THERE ANY NEW PROGNOSTIC SCORE FOR PERIPHERAL T-CELL LYMPHOMA?

D.M. Akkurd¹, H.H. Şahin², İ. Doğan³, V. Okan²

¹ Mersin City Training and Research Hospital Hematology

² Gaziantep University Sahinbey Research and

Practice Hospital Department of Hematology

³ Gaziantep University Department of Biostatistics

Objective: To compare with IPI the usefulness of new prognostic scores in patients with peripheral T-cell lymphoma (PTCL) from a single institution. **Methodology:** Sixty patients (30 male/30 female) with PTCL [anaplastic large-cell lymphoma (ALCL) 18, PTCL not otherwise specified 32 and other 10]. International Prognostic Index (IPI), Modified Glasgow Prognostic Score (mGPS), Geriatric Nutritional Risk Index (GNRI), The combined index of hemoglobin, albumin, lymphocyte, and platelet (HALP), Platelet to Lymphocyte Ratio (PLR), Neutrophil to Lymphocyte Ratio (NLR), albumin/globulin ratio(A/G), Prognostic nutritional index(PNI) were calculated as in the original references. **Results:** mGPS,GNRI,HALP, PLR,NLR,A/G and PNI have not significance to predict overall survival in patients with peripheral T-cell lymphoma(Table-1). **Conclusions:** IPI is still superior from all prognostic scores (mGPS,GNRI,HALP,PLR,NLR,A/G and PNI) to predict overall survival.

Variables in the Equation

Table-1

	B	SE	Wald	df	Sig.	Exp(B)	95,0% CI for Exp(B)	
							Lower	Upper
IPI	0,598	0,167	12,75	1	0	1,818	1,31	2,525
mGPS	0,001	0,244	0	1	0,996	1,001	0,621	1,614
GNRI	0,014	0,017	0,738	1	0,39	1,014	0,982	1,048
HALP	0,036	0,275	0,017	1	0,897	0,965	0,563	1,655
PLR	0	0,001	0,166	1	0,684	1	0,998	1,003
NLR	0,035	0,046	0,599	1	0,439	1,036	0,947	1,133
A/G	0,399	0,463	0,74	1	0,389	0,671	0,271	1,663
PNI	0,008	0,014	0,357	1	0,55	0,992	0,965	1,019

<https://doi.org/10.1016/j.htct.2022.09.1248>

MYELOMA

PP 14

RISK ASSESSMENT FOR NEWLY DIAGNOSED, FIT AND YOUNG PATIENTS WITH MULTIPLE MYELOMA, IN THE ERA OF NOVEL TREATMENT MODALITIES: ARE THERE ANY ADDITIONAL FACTORS TO BE UNDER CONSIDERATION?

Panayotis Kaloyannidis, Fatema Abdulla, Enas Mutahar, Haidar Hashim, Salman Harbi, Analie Estanislao, Solaf Ka

Adult Hematology & Stem Cell Transplantation Department, King Fahad Specialist Hospital

Objective: Multiple myeloma (MM) is considered a disease of elderlies however, 35-40% of newly diagnosed MM (NDMM) patients (pts) are ≤60 years (ys) old. Although young NDMM pts succeed better outcomes with the currently used treatment protocols, a considerable number of them (25-35%) succumb to MM, within 5 ys after diagnosis. We evaluated the

overall survival (OS) and the related risk factors, in NDMM pts aged ≤55 years and we designed a scoring system with predictive value on their long-term outcome. **Methodology:** Among 116 NDMM pts treated from 2010-20 in our center, 58 were ≤55 ys and 41% had advanced disease, 24% elevated LDH, 15% extramedullary disease (EMD) and 14% high-risk cytogenetic features. Following treatment with 3 (n=48) or 2 (n=10) agents of Velcade, Cyclophosphamide, Lenalidomide and DXM, 90% underwent autologous hematopoietic stem cell transplantation (AHSCT). Female gender, advance disease, EMD presence, elevated LDH and less than very good response pre-AHSCT, adversely affected the OS. **Results:** After a median follow up of 4 ys, the median OS was not reached however, approximately 25% of young NDMM patients died within 4 ys after diagnosis. Based on the aforementioned risk factors we created a risk scoring system which compared to the international staging system (ISS), sufficiently discriminated young NDMM patients who are at risk for poor outcome. The 4-year OS was superior for pts with 0-2 factors compared to those with 3-5 factors (86% vs. 44% respectively, p<0.001). **Conclusion:** Despite the current plethora of the available treatment agents, the heterogeneity in the outcomes among the NDMM pts, highlights the unmet need to establish appropriate criteria for personalized and more efficient treatment approaches, especially for the younger NDMM pts. In this study, we propose an easily applicable scoring system, which can discriminate younger NDMM pts who might need more intensive treatment aiming at prolonged survival rates.

<https://doi.org/10.1016/j.htct.2022.09.1249>

PLATELET DISEASES

PP 15

LONG-TERM OUTCOMES OF PATIENTS TREATED WITH CAPLACIZUMAB FOR IMMUNE-MEDIATED THROMBOTIC THROMBOCYTOPENIC PURPURA (ITTP): THE POST-HERCULES STUDY

Özgür Pektaş¹, Marie Scully², Javier de la Rubia³, Katerina Pavenski⁴, Ara Metjian⁵, Paul Knöbl⁶, Flora Peyvandi⁷, Spero Cataland⁸, Paul Coppo⁹, Johanna A. Kremer Hovinga¹⁰, Jessica Minkue Mi Edou¹¹, Rui de Passos Sousa¹¹, Sriya Gunawardena¹², Julie Lin^{12,13}

¹ Sanofi, Istanbul, Turkey

² Department of Haematology, University College London Hospitals, London, UK

³ Hematology Department, Internal Medicine, School of Medicine and Dentistry, Catholic University of Valencia and Hospital Doctor Peset, Valencia, Spain

⁴ Departments of Medicine and Laboratory Medicine, St. Michael's Hospital and University of Toronto, Toronto, ON, Canada

⁵ Division of Hematology, Department of Medicine, University of Colorado–Anschutz Medical Center, Denver, CO, USA

⁶ Department of Medicine 1, Division of Hematology and Hemostasis, Medical University of Vienna, Vienna, Austria

⁷ Fondazione IRCCS Ca' Granda Ospedale Maggiore Policlinico, Angelo Bianchi Bonomi Hemophilia and Thrombosis Center and Fondazione Luigi Villa, Milan, Italy, and Università degli Studi di Milano, Department of Pathophysiology and Transplantation, Milan, Italy

⁸ Department of Internal Medicine, Ohio State University, Columbus, OH, USA

⁹ Department of Hematology, Reference Center for Thrombotic Microangiopathies (CNR-MAT), Saint-Antoine University Hospital, AP-HP, Paris, France

¹⁰ Department of Hematology and Central Hematology Laboratory, Inselspital, Bern University Hospital, University of Bern, Bern, Switzerland

¹¹ Formerly Sanofi, Zwijnaarde, Belgium

¹² Formerly Sanofi, Lisbon, Portugal

¹³ Sanofi, Cambridge, MA, USA

Objective: The efficacy and safety of caplacizumab (CPLZ) for patients (pts) with immune-mediated thrombotic thrombocytopenic purpura (iTTP; also known as acquired TTP) were demonstrated in the Phase 3 HERCULES trial, with a 28-day follow-up period after end of treatment. Post-HERCULES (NCT02878603) evaluated the long-term outcomes of pts with iTTP treated with CPLZ during HERCULES, and the safety and efficacy of repeated CPLZ use for iTTP recurrence. **Methodology:** Over 3 years' follow-up, pts could receive CPLZ with therapeutic plasma exchange (TPE) and immunosuppressive therapy (IST) for iTTP recurrence. Safety was assessed during the overall study period in the intention-to-observe (ITO) population; TTP-related events (TTP-related mortality, recurrence, or major thromboembolic events) were assessed in pts without recurrence in HERCULES or prior to post-HERCULES (efficacy ITO population). Safety and efficacy were also evaluated during recurrences. **Results:** Of 104 pts enrolled, incidences of adverse events (AEs) were similar between pts treated with CPLZ +TPE+IST during HERCULES (n=75) and pts treated with TPE +IST only (n=29). TTP-related events occurred in 4/49 pts (8%) randomized to CPLZ vs 11/29 pts (38%) randomized to placebo. The first recurrence episode was resolved/resolving for all 13 pts treated with CPLZ for recurrence, including 9 pts with repeat CPLZ. The safety profile of CPLZ for recurrence was consistent with HERCULES. **Conclusion:** Over long-term follow-up, the safety profile of patients treated with CPLZ in combination with TPE+IST was generally similar to those who received IST+TPE only, with no observed increases in iTTP recurrence. Repeat use of CPLZ was efficacious, with no new safety concerns.

<https://doi.org/10.1016/j.htct.2022.09.1250>

OTHER DISEASES

PP 16

EFFICACY OF FUROSEMIDE IN METHOTREXATE CLEARANCE IN PATIENTS TREATED WITH HIGH DOSE METHOTREXATE

Saqib Khan¹, Tariq Muhammad², Yasmin Abdul Rashid¹

¹ Aga Khan University Hospital

² Khyber Teaching Hospital

Objective: Methotrexate was first used in 1947 as a chemotherapeutic drug in the treatment of acute lymphoblastic leukemia (ALL). Methotrexate has been extensively explored as an anticancer drug since that time. High dose methotrexate is a term used for doses above 1000mg/m². The objective of this study is to determine efficacy of Furosemide in methotrexate clearance in patients treated with high dose methotrexate. **Methodology:** It was a prospective cohort study carried out at the Oncology department of a tertiary care hospital, Pakistan for a period of one year. Total 80 patients were enrolled and all received daily hydration of at least 5L along with urine alkalization with sodium-bicarbonate and calcium rescue as per protocol. All patients were given Furosemide 40 mg three times a day. Methotrexate levels were monitored every 24 hours to follow its clearance. Data analysis was done by using IBM SPSS version 24. **Results:** The mean (SD) hospital stay in the current study was 4 (±1) days. Frequency of delayed methotrexate clearance was observed in 16 (20%) patients. The mean (SD) time of methotrexate clearance was 4 (±1) days. Renal injury was observed in 8 (10%) subjects, electrolyte imbalance in 12 (15%) subjects, and transaminitis in 11 (13.75%) subjects while mucositis was observed in 8 (10%) subjects. **Conclusion:** Our study concludes that furosemide is effective in methotrexate clearance in patients treated with high dose methotrexate. The use of furosemide reduces the cost and hospital stay. As furosemide is cheaper and easily available so it can be used easily in the methotrexate clearance.

<https://doi.org/10.1016/j.htct.2022.09.1251>

PP17

CART CELL THERAPY BLACK SHADOW IN HEMATOLOGICAL DISORDERS : SYSTEMIC REVIEW WITH META-ANALYSIS

Ghada EL Gohary

King Saud University

Aim: To determine the effect of CART therapy on hypogammaglobulinemia and bone marrow aplasia, and to determine the probable medications in management of hypogammaglobulinemia with other associated risk factors and complications. **Methodology:** Systematic search was conducted in 4

databases using the terms CART therapy, haematological malignancies, and hypogammaglobulinemia. Articles including patients with any haematological malignancies undergone CART therapy and assessment done on hypogammaglobulinemia were included. Following screening and selection of the articles, narrative synthesis, quality assessment, and meta-analysis were conducted **Results:** 1197 citations, 9 were finally included for meta-analysis comprising of 425 patients who were affected due to any haematological malignancies and had undergone CART therapy. The overall incidence rate was 35.35%. In all the studies, hypogammaglobulinemia was managed using IgG. Most of the patients across the studies had infection due to reduction in WBC count. The overall incidence of neutropenia following CART therapy was 59% lymphopenia was 82%, and B-cell aplasia was 49.5%. **Conclusion:** The effective way for management of hypogammaglobulinemia was using IgA antibody. The overall incidence of hypogammaglobulinemia and WBCs was difficult to conclude as majority of the studies were of low and fair quality and were collected at different time points after administration of CART therapy. Thus, good quality clinical trials, open label trials or RCT are required. Hypogammaglobulinemia increases with a decrease in neutrophils, lymphocytes, and B-type cells leading to variable infection.

<https://doi.org/10.1016/j.htct.2022.09.1252>

PP18

RECTAL CANCER DISTANCE TO THE ANAL VERGE AND THE T STAGING: MAGNETIC RESONANCE IMAGING FINDINGS

Abdalraouf Omar¹, Fatma Algledy²,
Najat Amar³, Mufaida Elmusrati⁴

¹ Albadri Polyclinic and Tripoli University Hospital, Tripoli, Libya

² National Center of Disease Control – Libya

³ Oil Clinic, Tripoli, Libya

⁴ Tripoli University Hospital and University of Tripoli, Tripoli, Libya

Objective: This study sought to determine the magnetic resonance imaging (MRI) T staging and the rectal cancer (RC) distance to the anal verge in patients treated in radiotherapy department of Tripoli University Hospital. **Methodology:** An observational study was conducted in Radiotherapy department at Tripoli University Hospital retrospectively from January 1, 2018 to December 31, 2020 for total number of 73 patients whom met the inclusion criteria; 18-year-old or more, male and female with primary RC, T2 or more. distance metastasis or secondary RC were excluded. **Results:** Patients were 38 female and 35 male. Patient less than 50 years old was 25% and 38% was between 50-69 years old. patient at 70 years old or older was 10%. The low rectal cancer, less than 5 cm to the anal verge, is in 38.4% of the patients, with most of the patients at T2 staging (45.5%). While 19.2% was in the mid rectum, 5-10 cm to the anal verge, the T2 was 9%. Regarding the high rectum, more than 10 cm to the anal verge, it was

present in 42.5%, of which 45.5% was in T4b. **Conclusion:** Rectal cancer was less commonly in the mid rectum. in the low rectum it was commonly T2 stage and in high rectum T4b was predominant. Further studies are needed.

<https://doi.org/10.1016/j.htct.2022.09.1253>

PP19

A CASE OF FASCIOLOSIS PRESENTING WITH SEVERE HYPEREOSINOPHILIA

Metban Mastanzade, Arzu Şenol, Alper Koç

Elazığ Fethi Sekin City Hospital

Objective: *Fasciola hepatica* is a parasitic trematode and infects livers of various mammals and rarely infects human liver. Frequently eosinophilia is detected in laboratory findings, but it is generally mild or moderate as with other parasitic infections. Here we present a patient with Fasciolosis as the cause of severe hypereosinophilia. **Case report:** A 66-year-old female patient presented with weight loss, nausea and abdominal pain for one month. Her physical examination was unremarkable except for mild hepatomegaly. Her laboratory tests were as follows; leukocytes 29900/mm³, eosinophils 21550/mm³ (%71.9), ALP 379 IU/L, LDH 278 IU/L, GGT 53 IU/L, CRP 30 mg/dl. All other etiological tests including primary secondary causes were negative. Abdominal MRI revealed focal patchy nodular lesions. *Fasciola hepatica* IHA (1/2560) was positive. **Results:** After the diagnosis, the patient was administered 2 doses of triclabendazole (10 mg/mg) at 5 day intervals. In the 3rd month of the treatment, the control eosinophil count decreased to 480/mm³, and the patient was free of any symptoms. **Conclusion:** Severe eosinophilia (>5000/mm³) is generally associated with malignant diseases, hypereosinophilic syndrome or primary hematologic disorders. But it would be useful to consider fasciolosis in hypereosinophilia patients who are sheep and cattle breeder and present with gastrointestinal system complaints such as jaundice and abdominal pain.

<https://doi.org/10.1016/j.htct.2022.09.1254>

PP 20

RITUXIMAB-INDUCED SEVERE ACUTE THROMBOCYTOPENIA IN A PATIENT WITH SPLENIC MARGINAL ZONE LYMPHOMA

Taha Ulutan Kars, Zahit Furkan Yorgancı,
Osman Yaşkıran, Atakan Tekinalp

Necmettin Erbakan University Meram Faculty of Medicine

Objective: Rituximab, which is widely used in the treatment of B-cell lymphoma, is a chimeric monoclonal antibody directed against the CD20 antigen. Rituximab has many side effects, mainly allergic and neurological. Rituximab may cause thrombocytopenia in the long term after

administration. Rare cases with rituximab-induced acute thrombocytopenia have been reported in the literature. **Case report:** A 51-year-old female patient who newly diagnosed splenic marginal zone lymphoma recieved rituximab as first line therapy. Petechiae occurred in the lower extremities on the day following rituximab administration. The blood test showed a severe drop in the platelet count from 112,000/ μ L to 5,000/ μ L. Blood peripheral smear evaluation confirmed severe thrombocytopenia. **Results:** There was no change in hemoglobin or white blood cell levels. After the diagnosis of rituximab-induced acute thrombocytopenia, thrombocyte suspension was administered due to the risk of bleeding. Close clinical and laboratory observations were made. The platelet count began to rise gradually in the following period. Before the second week of rituximab administration, the platelet count was 122,000/ μ L. **Conclusion:** Rituximab has a widespread use, especially in malignancies and autoimmune diseases. Like many monoclonal antibodies, rituximab has several side effects. Thrombocytopenia is a long-term side effect associated with rituximab, and rituximab-induced severe acute thrombocytopenia has been rarely reported. Therefore, it should be kept in mind that severe acute thrombocytopenia may develop after rituximab administration.

<https://doi.org/10.1016/j.htct.2022.09.1255>

PP 21

VITAMIN B 12 DEFICIENCY MIMICKING THROMBOTIC MICROANGIOPATHY: A CASE REPORT

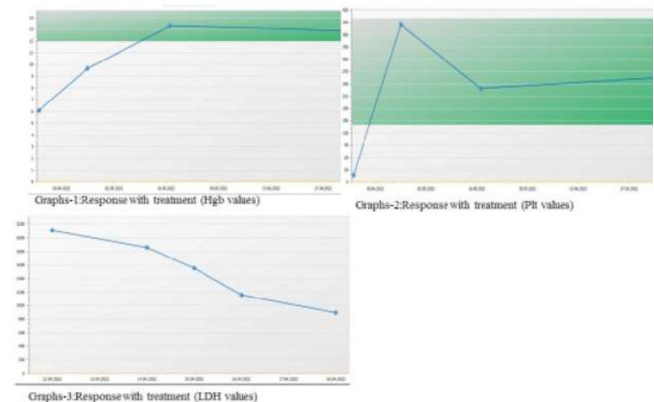
Müzeyyen Aslaner Ak¹, Selime Yiğit²,
Gizem Süren², Şehmus Ertop¹

¹ Zonguldak Bulent Ecevit University Faculty of Medicine Department of Hematology

² Zonguldak Bulent Ecevit University Faculty of Medicine Department of Internal Medicine

Objective: Vitamin B12 has an important role in DNA synthesis, erythrocyte development and neurological functions by the transfer of one-carbon methyl groups. Vitamin B 12 deficiency may mimic Thrombotic Microangiopathy (TMA) and lead to pseudo-thrombotic microangiopathy (pseudo-TMA). Early recognition of pseudo-TMA is important because treatment with vitamin B 12 replacement is quite simple and effective. **Case report:** A 66-year-old female patient was admitted to the emergency department with complaints of fatigue. CBC values Hb 3.8gr/dL , Hct 11.3%, MCV 115 fL , platelets 19000/mm³, WBC 6400/mm³, ind.bil.1.5 mg/dL, LDH 2111U/L . In peripheral blood smear (PBS), macroovalocytes, anisopoikilocytes, schistocytes, hypersegmented neutrophils and a normoblast with megaloblastic features (figure-1) were observed. Thrombocytopenia and the presence of schistocyte initially supported TMA. **Methodology:** Blood was drawn from the patient for the ADAMTS-13 test. While concurrent steroid treatment with fresh frozen plasma (FFP) was started, plasmapheresis preparation was also made. The patient's vitamin B12 level was 50 pg/mL The patient was started on vitamin B12

as 1000 mcg IM. Following clinical recovery, hemoglobin and platelets stabilized, the hemolysis panel indicated a steady improvement (graphs 1, 2, 3). **Results Conclusion:** TMA symptoms can be mimicked by severe vitamin B12 deficiency. Rapid and accurate diagnosis of pseudo-TMA and initiation of parenteral vitamin B 12 replacement can prevent unnecessary and expensive diagnostic investigations and long-term plasma exchange treatments. Our case, has demonstrated the importance of considering vitamin B12 insufficiency in cases presenting with TMA and the value of carefully examining PBS in the identification of megaloblastic anemia.



<https://doi.org/10.1016/j.htct.2022.09.1256>

PP 22

QUALITY OF LIFE IN HEMATOLOGICAL PATIENTS IN THE POST-COVID ERA

Weronika Lebowa, Karol Miklusiak,
Ositadima Chukwu, Agnieszka Giza,
Tomasz Sacha

Department of Haematology, University Hospital,
Jagiellonian University Medical College, Cracow,
Poland

Objective: Currently, restrictions related to the COVID-19 pandemic have been lifted in many countries. However, the pandemic could still have impact on the current quality of life of patients, especially oncological ones. Our study aimed to determine the impact of the COVID-19 pandemic on the functioning of patients with hematological diseases. **Methodology:** This is a prospective survey-based study. We used the EORTC QoL questionnaire in the population consisting of 32 patients: 22 with lymphoma (69%), 4 with hairy cell leukemia (13%), 3 with myelofibrosis (9%), 1 with acute myeloid leukemia (3%), 1 with chronic myeloid leukemia (3%), 1 with non-oncologic disease (3%). The median age was 50.5 years (ranged 21 – 76). The questionnaires were collected between May and June 2022. Statistical analysis was performed using R software (R version 4.0.3.). **Results:** 41% of patients had a COVID-19 infection confirmed by PCR test. 38% of them were hospitalized, 80% of whom required oxygen therapy. Quality of life was 62.5 (16.7 – 83.3), functioning scales: physical

functioning 86.7, role functioning 66.7, emotional functioning 83.3, cognitive functioning 83.3, social functioning 66.7; symptom: fatigue 33.3, insomnia 33.3. Patients who required oxygen therapy had higher scores on the financial impact scale than those who didn't, 66.7 vs 0, $p = 0.0261$. **Conclusion:** Role and social functioning was the worst item among functioning scales. Women had significantly higher social functioning than men. Fatigue and insomnia were the most burdensome symptoms assessed on the symptom scales. No significant differences were found in scores of EORTC between patients who reported COVID infection and those who didn't. The limitation of this study is a relatively small research group. The future direction is to perform a similar analysis on a larger population.

<https://doi.org/10.1016/j.htct.2022.09.1257>

PP 23

ECULIZUMAB DOSE ADJUSTMENTS DURING PREGNANCIES IN PAROXYSMAL NOCTURNAL HEMOGLOBINURIA: A SINGLE CENTER EXPERIENCE.

Semra Aydin¹, Valentina Giai², Stefano D'ardia², Giorgia Iovino³, Chiara Frairia², Irene Urbino², Marco Cerrano², Eloise Beggiato⁴, Ernesta Audisio²

¹ Department of Oncology, Hematology, Immuno-Oncology and Rheumatology, University Hospital of Bonn, Bonn

² Department of Oncology, Hematology, A.O.U. Città della Salute e della Scienza, Turin, Italy

³ Servizio di Oncologia ed Ematologia, Cirie, Italy

⁴ Unit of Hematology, Department of Oncology, University of Turin, Turin, Italy

Objective: Paroxysmal nocturnal hemoglobinuria (PNH) has always been considered a relative contraindication for pregnancy. The use of eculizumab has reduced morbidity and mortality of fetus and mother. Dose adjustments are often required due to emerging breakthrough hemolysis, no standard recommendations are currently available in this setting. Here we report our single hematology center experience on breakthrough hemolysis and eculizumab dose adjustments during PNH pregnancies. **Methodology:** Clinical data of four pregnancies from three PNH patients are reported. Two of them were already on standard dosage eculizumab when pregnancies were diagnosed. Their baseline PNH clone sizes were 89.5% and 97.5% on granulocytes and 38% and 90% on erythrocytes, respectively. In both cases low molecular weight heparin-prophylaxis was started when pregnancy was diagnosed. The third 26 year old patient with a baseline PNH clone of 8.8% started treatment at the beginning of her 2nd trimester. **Results:** The 26 year old patient was stable on 900 mg Eculizumab until 12 weeks post-partum. The other two developed breakthrough hemolysis during their third trimesters. Eculizumab dosing was increased initially from 900mg

bi-weekly to 900 mg weekly and subsequently to 1200 mg biweekly. The 28 year old patient with the largest clone underwent two pregnancies and required even a 1200mg weekly dosage in her first pregnancy until four weeks post-partum. All four babies were delivered without complications. **Conclusion:** Eculizumab dose adjustments up to 1200 mg biweekly as well as interval shortening from bi-weekly to weekly administration seems effective and safe in breakthrough hemolysis control during pregnancy in PNH. Dose escalations did not impact on birth or development of the babies.

<https://doi.org/10.1016/j.htct.2022.09.1258>

PP 24

ALECTINIB-RELATED ERYTHROCYTE MEMBRANE CHANGES, NON-IMMUNE HEMOLYSIS AND ERYPTOSIS

Emine Gulturk

Bakirkoy Dr Sadi Konuk Hospital

Objective: Alectinib is an anaplastic lymphoma kinase (ALK) inhibitor which standard initial treatment for patients with advanced ALK rearranged non-small-cell lung cancer (NSCLC). The current study was planned by the incidental observation of non-immun hemolysis signs in several alectinib-treated patients, and its aim was to comprehensively characterize erythrocyte changes under this drug. **Methodology:** We analyzed retrospectively 13 patients treated with alectinib for ALK+ NSCLC at the Bakirkoy Sadi Konuk and Kartal Dr Lutfi Kırdar Hospital Medical Oncology Department. Almost all patients were consulted with the hematology clinic because of anemia and elevated lactate dehydrogenase during alectinib. Laboratory tests requested for characterization of anemia included reticulocyte count, indirect bilirubin, haptoglobin, direct antiglobulin test, and LDH. All patients were examined by peripheral smear. **Results:** The analyzed patients, hematological tests results are showed that: Anemia was present in approximately all of patients and was mostly mild, (lowest hgb 8.5gr/dl). Reticulocytes were increased and the direct antiglobulin (Coombs) test was negative in all patients. Peripheral blood smears showed signs of eryptosis, abnormal red blood cell morphology in all patients, with anisocytosis, a predominance of acanthocytes, as well as occasional echinocytes, spherocytes, dacrocytes and rare fragmentocytes. **Conclusion:** We have reported 13 cases of significant alterations in erythrocyte morphology secondary to alectinib. Patients predominantly showed mild anemia, but one patient developed significant Coombs-negative hemolysis. In this case, hemolytic markers improved after alectinib was discontinued. This study highlights the need for both clinicians and haematologists to be observant for unrecognised off-target effects of novel agents.

<https://doi.org/10.1016/j.htct.2022.09.1259>

PP 25

GLOMERULAR MICROANGIOPATHY WITH
MARKED SYSTEMIC THROMBOTIC
MICROANGIOPATHY SHORTLY AFTER
BORTEZOMIB IN A NEWLY DIAGNOSED
POEMS SYNDROME PATIENT

Tarık Onur Tiryaki¹, Akın Işık², Simge Erdem¹,
Nurana Güller³, Gamze Kemeç², Halil Yazıcı³,
Yasemin Özlük⁴, Işın Kılıçaslan⁴,
Sevgi Kalayoglu Beşişik¹

¹ Istanbul University Istanbul Faculty of Medicine,
Internal Medicine Department/Hematology Division

² Istanbul University Istanbul Faculty of Medicine,
Internal Medicine Department

³ Istanbul University Istanbul Faculty of Medicine,
Internal Medicine Department/Nephrology Division

⁴ Istanbul University Istanbul Faculty of Medicine,
Pathology Department

Abstract: The dipeptide boronic acid analogue bortezomib as a potent and selective inhibitor of the proteasome is used for the treatment of plasma cell dyscrasias such as multiple myeloma (MM). Bortezomib may induce glomerular microangiopathy (GMA) with or without systemic thrombotic microangiopathy (TMA) in which vascular endothelial growth factor-nuclear factor (VEGF) - κ B pathway could be involved. MM itself can cause TMA but primarily at presentation. **Case report:** We present a case with GMA associated with clinical features supporting systemic TMA shortly after bortezomib. **Case:** A 54-year-old woman has been diagnosed as having POEMS syndrome. She had symmetric mild degree of peripheral neuropathy, scleroatrophic skin lesions, Raynaud's phenomenon, and retinopathy. IgG kappa type paraproteinemia with a monocytic increase of plasma cells and increased pulmonary artery pressure contributed to the diagnosis. Bortezomib based treatment was started. **Methodology:** At the 20th day she developed severe dyspnea. Bilateral pleural effusion and acute kidney failure with thrombocytopenia and microangiopathic hemolytic anemia were documented. Urgent steroid and plasmapheresis were started. ADAMTS13 level proved to be within normal and plasmapheresis did not contribute to improvement. She commenced on hemodialysis and kidney biopsy was decided. Light microscopy findings revealed glomerular capillary thrombus, basement membrane thickening and segmental **Results:** duplication. Hyperplastic arteriolar changes were present. No immune deposits were detected by immunofluorescence microscopy. Biopsy findings were diagnostic for thrombotic microangiopathy. The clinical picture deteriorated as sleepiness and confusion. Cranial imaging and cerebrospinal fluid analysis showed no abnormality. Eculizumab with off-label approval contributed to stabilization but no improvement. **Conclusion:** Conclusion: Proteasome inhibitors associated with TMA may be life-threatening along with organ dysfunction due to microangiopathy-related ischemia. Membrane attack complex (C5b-9) deposition was found on endothelial cells

in culture exposed to plasma from patients during the acute phase of the disease which may point to complement blockade benefit.

<https://doi.org/10.1016/j.htct.2022.09.1260>

PEDIATRIC HEMATOLOGY ABSTRACT CATEGORIES

COAGULATION AND FIBRINOLYSIS DISORDERS

PP 26

THE SUCCESSFUL MAJOR SURGERY IN A
PATIENT WITH INHERITED FVII DEFICIENCY
AND A HUGE NASOPHARYNGEAL
ANGIOFIBROMA

Aysegul Unuvar¹, Levent Aydemir²,
Mehmet Barbuoglu³, Sifa Sahin¹,
Mustafa Bilici¹, Deniz Tugcu¹,
Gulsah Tanyildiz¹, Zeynep Karakas¹,
Serap Karaman¹

¹ Istanbul University, Istanbul School of Medicine,
Division of Pediatric Hematology&Oncology

² Department of Otorhinolaryngology, Head and
Neck Surgery

³ Department of Radiology, Division of
Neuroradiology

Objective: The bleeding phenotype of patients with inherited FVII deficiency is variable, and epistaxis is one of the most frequent symptoms. Interestingly, the bleeding risk does not correlate with the level of FVII activity. The severity of FVII deficiency and the type of surgery are not determinants of the optimal management of surgery, the doses and the duration of rFVIIa therapy are widely variable. The aim of this study is to present our successful experience in a 16-year-old boy with inherited FVII deficiency and a huge nasopharyngeal angiofibroma with a very high risk of bleeding **Case report:** The patient was referred with recurrent epistaxis in the last 6 months and he was diagnosed as an inherited FVII deficiency (FVIIC:29%, FVII inhibitor negative with positive family history). Tranexamic acid (10days) and rFVIIa (2doses) were used with success in the management of this surgery. Since this surgery may cause life-threatening bleeding, endovascular particle embolization was done to the important vessels feeding the mass one day before surgery without rFVIIa support. No bleeding or thrombosis were observed in our patient. **Conclusion:** In conclusion, a life-threatening major surgery was successfully done for a patient with inherited FVII deficiency and a huge angiofibroma. However, perioperative management of patients with FVII deficiency still remains a major challenge and clinical trials are needed to provide evidence-based optimal management of surgeries. And, angiofibroma should be thought in the differential diagnosis of epistaxis.

<https://doi.org/10.1016/j.htct.2022.09.1261>

RED BLOOD CELL DISORDERS

PP 27

ROLE OF SERUM HEPcidIN AND RETICULOCYTE HEMOGLOBIN CONCENTRATION IN EVALUATION OF ANEMIA IN ULCERATIVE COLITIS PATIENTS

Amr Mohamed Gawaly Gawaly, Samar Ammar, Medhat Ghazy, Maaly Mabrouk

Tanta University

Objective: One of the most common extra-intestinal signs of ulcerative colitis (UC) disease is anemia, which has a considerable influence on patients' quality of life. **AIM:** The aim was to evaluate the role of serum hepcidin and reticulocyte hemoglobin concentration (CHr) in the study of anemia in UC patients. **Methodology:** We recruited 80 UC patients and 30 healthy individuals of matched age and sex as controls. Subjects were subdivided into three groups – Group I: 50 anemic UC patients, Group II: 30 nonanemic UC patients, and Group III: 30 healthy controls. **Results:** CHr showed a statistically highly significant decline in Group I than Groups II and III. Serum hepcidin showed a significant difference between Groups I, II, and III. Also, a significant negative correlation between CHr, serum hepcidin and severity of UC and a significant positive correlation between CHr and hemoglobin level, MCV, serum ferritin, and transferrin S. While serum hepcidin had a significant positive correlation with hemoglobin level, MCV, serum ferritin, transferrin S., and CHr. **Conclusion:** CHr had an excellent performance in prediction of iron-restricted anemia and was the test of best performance in prediction of iron-deficiency anemia \pm ACD. Serum hepcidin had an excellent performance in prediction of ACD.

<https://doi.org/10.1016/j.htct.2022.09.1262>

IMMUNODEFICIENCIES / NEUTROPHIL DISEASES

PP 28

GRISCELLI SYNDROME TYPE 2 –CLINICAL APPROACH AND CASE REPORT

Konul Baghirova, Gular Mammadova, Avesta Allahverdiyeva, Narmin Eyvazova, Narmin Verdiyeva, Agarza Agayev, Samira Hasanova, Valeh Huseynov

Azerbaijan National Hematology and Transfusiology Center

Objective: Griscelli syndrome type 2 is rare autosomal recessive disorder caused by a defect in the RAB27A gene, which affects a melanosome-anchoring complex in melanocytes, affecting release of cytolytic granules from T and NK cells. Children with GS type 2 develop an uncontrolled T-

lymphocyte and macrophage activation syndrome known as hemophagocytic syndrome (HS) or hemophagocytic lymphohistiocytosis (HLH). We describe a 3 years old girl patient classic features of Griscelli syndrome type 2 **Case report:** A 3-year-old girl was admitted to hematology with complaints of LAP, hepatosplenomegaly and pancytopenia (WBC- 3080/ μ l, Hb-7.6 g/dl, Neutr.-350/ μ l, PLT - 165000/ μ l). The patient's condition was below the percentile, her skin was bronze, her hair was silver-grey. HLH criteria were met (triglycerides 458 mg/mL, ferritin 3445 ng/mL, fibrinogen 180 mg/dl). Morphology of the bone marrow was hypocellular, signs of dyserythropoiesis (stage I) and megakaryocytes were reduced **Methodology:** According to the clinical and laboratory data (hepatosplenomegaly, increased ferritin, hypertriglyceridemia, pancytopenia, hyperthermia resistant to antimicrobial therapy, silver-gray hair, pigment balls of hair seen light microscope) and the death of another undiagnosed child in the family, suggested likely primary HLH and GS. As a result of genetic analysis (homozygous mutation c.514_518del-CAAGC(p.GLN172Asnfs*,rs767481076)1 in the RAB27A gene), the diagnosis of GS type 2 was confirmed. **Results:** The patient was treated according to the HLH 2004 protocol. CSA levels were measured once a week. IVIG support was given based on IgG levels. HSCT was planned from patient's healthy HLA-matched sibling, but HSCT was delayed because the brother was infant. After 45 weeks of maintenance therapy, etoposide was discontinued, dose of dexamethasone was reduced to 5 mg/kg, but CSA was continued at the same dose. Control studies are carried out once a week. As far as possible HSCT is planning **Conclusion:** The prognosis of patients with Griscelli syndrome is poor. It is usually rapidly fatal within 1-4 years without aggressive treatment and bone marrow transplantation at onset of an accelerated phase. HSCT is more successful when implemented early course of the disease. Palliative care includes treatment and prophylaxis care infections and immunosuppressor therapy in accelerated phases. Some patients have died after transplantation, but others have had lasting remissions

<https://doi.org/10.1016/j.htct.2022.09.1263>

LEUKEMIA

PP 29

THE COURSE OF TOXIC HEPATITIS IN LEUKEMIC PATIENTS AT THE STAGE OF SUPPORT THERAPY.

Mireldar Babayev, Ahmadova Afaq

National Hematology and Transfusiology Center

Objective: One of the main tasks in the treatment of acute leukemia is to prevent the development of complications of chemotherapy, as well as the timely choice of the correct tactics for the treatment of complications. Because forced breaks associated with complications negatively affect the end result

of leukemia treatment. Practice shows that one of the organs affected by chemotherapy is the liver, and its damage directly depends on the toxicity and duration of chemotherapy. Our task was to conduct research work in this area, and to study toxic liver lesions in patients with leukemia. Before that, we carried out similar work at the stages of induction and consolidation of treatment of acute leukemia in children. And this period of research work is devoted to the supportive stage of therapy in patients. **Objective:** To study the frequency of toxic liver damage in children with acute leukemia during support therapy, to choose treatment tactics according to the severity of toxic hepatitis. **Methodology:** The study group included 51 children with primary acute lymphoblastic leukemia who completed the induction stage with complete remission and retained this result for the entire period of consolidation. The age of the patients ranged from 2.5 years to 15 years. Of these, there were 28 boys and 23 girls. The patients were from Baku and the regions of the republic. Treatment of acute lymphoblastic leukemia was carried out according to two branches of the Moscow – Berlin – 2015 program: B and T ÌmRG. The protocols of maintenance therapy of these branches do not differ, and both begin with the 31st week of the general program, end on the 104th. Each protocol consists of 8 stages of a combination of chemotherapy drugs Metotreksat + 6-Mercaptopurine, which last for 6 weeks and alternate with two-week courses of reinduction - Deksametazon + Vinkristin. Before the start of maintenance therapy, all patients with leukemia confirmed the preservation of the previously achieved remission, and the functional and organic state of the liver. With positive results, the continuation of leukemia treatment began. And when the symptoms of toxic hepatitis were detected, the severity was determined. According to this indicator, 3 forms of flow were issued: light, medium-heavy and heavy forms. The tactics of conducting therapy of each form were chosen by us. **Results:** Of 51 patients, 42 had toxic hepatitis (82%). It was mild in 12 patients (23.5%), moderate in 26 children (50.9%), and severe in 4 children (7.8%). In the mild form of hepatitis, patients were prescribed intravenous administration of Riboksin + Aevit (orally) for 10-14 days, or alternatively, per os Ursobil + Aevit. This combination made it possible to restore all clinical and laboratory parameters in patients within 14-21 days, and at the same time, without interrupting chemotherapy. Moderate and severe forms of hepatitis occurred mainly during the period of reinduction (54.7%). The administration of intravenous adeomethionine (Heptral) in the form of monotherapy for 8-12 days allowed continuous reinduction courses. Following him, the administration of an oral combination of Ursobil + Lipoic acid + Aevit for 14-21 days allowed to preserve the long-term effect. In severe hepatitis, chemotherapy was suspended, and patients were prescribed intravenous adeomethionine (Heptral) in combination with oral Ursobil + Aevit for 10-14 days, and along with this detoxification therapy was carried out in parallel. Such treatment gave an improvement in clinical and laboratory parameters. Subsequently, intensive therapy was suspended, and chemotherapy was started accompanied by

Ursobil + Aevit + Lipoic acid for the next two weeks. This choice of therapy allowed us to preserve the restored indicators for a long time. There were no deaths or severe complications from toxic hepatitis in any case.

<https://doi.org/10.1016/j.htct.2022.09.1264>

HEMOGLOBINOPATHIES (SICKLE CELL DISEASE, THALASSEMIA ETC...)

PP 30

RARE UNSTABLE ALPHA GLOBIN VARIANT HB TAYBE (HBA1:C.118_120DELACC) WITH HBA2 POLY A MUTATIONS, CAUSES TO HEMOLYTIC ANEMIA IN TWO CASES FROM AZERBAIJAN

AghaRza Aghayev, Khuraman Jafarova,
Afsana Mammadova, Zenfira Mirzeyeva,
Valeh Huseynov

National Hematology and Transfusion Center, Baku,
Azerbaijan

Objective: Sequence variants are usually silent and rarer in α -globin, some may lead to an unstable protein with hemolytic or thalassemic phenotype. The most common HBA variant is ConstantSpring which is leading to an unstable elongated protein chain. Others may be due to ins/del in the α -globin, one of them Hb-Taybe caused deletion of Thr residue at codon 40 of the HBA1. We report, for the first time, 2 cases with hemolytic anemia due to the presence of Hb-Taybe in *trans* with HBA2 poly-A mutations. **Methodology:** Patients were managed in the Thalassemia Unit of the National Hematology Center. Detailed pedigrees are drawn, medical recordings are reviewed and peripheral blood samples are collected. Sanger sequencing was performed with *in house* designed primers (HBA1, NM_000558.5 and HBA2, NM_000517.6) on genome analyser (ABI3500). Deletion and duplication analysis is performed by MLPA. **Results:** P-1: A 4-yr-old male who was diagnosed at the age of 1 yr with congenital hemolytic anemia. He presented with jaundice, the blood film showed moderate hypochromia and anisopoikilocytosis. He was transfusion dependent. P-2: A 45-yr-old female who was diagnosed at the age of 5 yr with congenital hemolytic anemia. She underwent splenectomy at the age of 32 yr due to moderate anemia. After splenectomy she was not transfusion dependent. Relevant clinical and laboratory data is presented at table. **Conclusion:** The clinical presentation is variable from mild hemolytic anemia to regular transfusion requirement. One patient had to have splenectomy in order to ameliorate the transfusion requirement. This study supports the requirement of α -globin gene analyses, and a careful evaluation of cases with hemolytic anemia, particularly in populations where thalassemias are endemic, in order to avoid missing any of the rare globin variants and to offer accurate genetic counseling.

	P-1	P-2
Age at diagnosis (yr)	1	5
Consanguinity of parents	-	-
Spleen size below the left costal margin (cm)	3	underwent splenectomy
Cholelithiasis	+	-
Hb (g/dL)	6.1	8.4
RBC ($10^6/\mu\text{L}$)	2.93	3.01
MCV (fL)	76.8	108
MCH (pg)	20.8	27.9
Hb A2 (%)	1.7	1.7
Hb F (%)	6	0.1
Serum Iron ($\mu\text{g/dL}$)	113	149.9
Serum Ferritin (ng/ml)	115.8	1623
LDH (units/L)	-	554
Total bilirubin (mg/dl)	1.91	2.93
Direct Bilirubin (mg/dl)	0.62	0.76

<https://doi.org/10.1016/j.htct.2022.09.1265>

PP 31

HBH DISEASE AND SYSTEMIC LUPUS ERYTHEMATOSUS

Valeh Huseynov, Afag Nasibova,
Sevinj Nabiyeva

Azerbaijan National Hematology and Transfusiology
Center

Objective: The association between thalassemia and systemic lupus erythematosus (SLE) is very rare. There are many articles in the literature showing that patients diagnosed with SLE with Beta-Thalassemia have a more severe hemolytic picture. The combination of Alpha thalassemia and SLE was first reported in an article published on January 30, 2021, by the staff of Guangzhou Hospital in the People's Republic of China. Our report is about combination of HbH disease and SLE, too. **Case report:** A 31-year-old female patient with HbH disease who had been irregularly monitored by a hematologist for 12 years received a blood transfusion for the first time during her 4th pregnancy and has not seen a hematologist since. At 12 weeks of gestation (7th pregnancy), a severe hemolytic anemic clinic was observed and erythrocyte mass transfusion was initiated. However, as different types of allergic reactions were observed during and after hemotransfusions autoimmune tests were held. **Methodology:** As a result, Direct Antiglobulin Test (DAT), Anti Nuclear Antibody (ANA), and anti-dsDNA positive, complement C3 levels were found below standard. The diagnosis of SLE was confirmed based on the fact that the patient's previous 6 pregnancies resulted in miscarriages and stillbirth. At a later stage, as a result of detailed instrumental and laboratory examinations, she was diagnosed with Lupus nephritis and steroid treatment was started under the control of a nephrologist. **Results:** Unit erythrocyte mass was transfused during cholecystectomy in this patient who was taken to the hospital with seizure pain in the right subcostal area that suddenly began at 22 weeks of gestation. 24-week pregnancy was ceased due to

intrauterine growth retardation. In the next month of follow-up, during the hospitalization 7 units of washed erythrocyte mass were transfused to the patient who was brought to the hospital with severe anemia after positive Covid-19 PCR analysis. **Conclusion:** In case published about the first patient with HbH disease and SLE it was reported an increase in the severity of anemia and the maintenance of Hb value in the range of 9.0-10.0 g / dl with steroid. According to our researchs there were found similarities between the outcomes of these two studies. Studies suggest that SLE patients with severe hemolytic clinics in regions with a high prevalence of thalassemia should be investigated for hemoglobinopathies.

<https://doi.org/10.1016/j.htct.2022.09.1266>

TRANSFUSION MEDICINE / APHERESIS / CELL PROCESSING

PP 32

EVALUATION OF CLINICAL AND LABORATORY FINDINGS OF THERAPEUTIC PLASMAPHERESIS IN CHILDREN

Buğra Tutun¹, Defne AY Tuncel²,
Seda Turgut³, İlknur Arslan^{4,5}

¹ Adana City Education and Research Hospital

² Adana City Education and Research Hospital,
Department of Pediatrics

³ Adana City Education and Research Hospital,
Department of Pediatric Hematology and Oncology

⁴ Adana City Education and Research Hospital,
Department of Pediatric Intensive Care Unit

⁵ Adana City Education and Research Hospital,
Department of apheresis

Objective: Therapeutic plasmapheresis is an extracorporeal treatment method. The abnormal component of the patient's plasma is removed from the blood and replaced with the remaining blood components with a selected replacement fluid. We aimed to evaluate the demographic characteristics, procedure indications, procedure methods, differences between pre- and post-procedure laboratory parameters, and procedure-related complications of pediatric patients who underwent therapeutic plasma exchange (TPE). **Methodology:** Pediatric patients who underwent therapeutic plasmapheresis in Adana City Training and Research Hospital between 2018-2021 were included in our study. In this period, the number of pediatric patients who underwent therapeutic plasmapheresis was 61, and the total number of procedures was 238. The data of the patients were obtained from the files of the apheresis unit and the hospital registry system by retrospective analysis. Statistical analysis of the study was made with the SPSS v20 program. **Results:** 25 patients were female, 36 patients were male. Youngest patient was 6 months old and eldest was 17 years old. Patients weight range was between 5 and 104 kilograms. 191 of the procedures were TPE, 47 of them were lipid apheresis. The most common indications were hepatic failure, familial hyperlipidemia, neurological disorders, hematological disorders, sepsis with MODS and

intoxications. 119 transactions were in ASFA category-1. Complications were observed on 59 (%24,8) procedures. **Conclusion:** The most common complications are; vascular access related (obstruction) (21/59), hypotension (11/59), urticaria (7/59), technical malfunctions (7/59) and hypocalcemia (4/59). No exitus was observed due to the procedures. Therapeutic plasmapheresis procedure doesn't cause serious undesirable changes in laboratory values and serious complications are rare. Therapeutic plasmapheresis can be safely applied to pediatric patients in appropriate indications by making necessary adjustments.

<https://doi.org/10.1016/j.htct.2022.09.1267>

PEDIATRIC ONCOLOGY ABSTRACT CATEGORIES

LYMPHOMAS

PP 33

NON-HODGKIN'S LYMPHOMA: A RETROSPECTIVE ASSESSMENT OF CLINICAL FEATURES AND TREATMENT OUTCOMES

Zeynep Deniz Tutun, Ganiye Begül Küpeli, Buğra Tutun

Adana City Research and Training Hospital

Objective: The purpose of our study is to evaluate the demographic and clinical characteristics of pediatric Non-Hodgkin's Lymphoma (NHL) patients diagnosed and followed at our center, and also describe their survival rates and possible associations between outcomes and clinical features and to compare these data with the published reports from other clinical centers. **Methodology:** Children with NHL who were followed up and treated at Adana City Training and Research Hospital between 2013 and 2021 were included in the study. A total of 60 patients' files were collected and analyzed retrospectively. Age, gender, time of diagnosis, histopathological subtypes, primary location of the tumor, extranodal involvement, stage, bone marrow (BM) and central nervous system (CNS) involvement status, lactate dehydrogenase (LDH) levels at the time of diagnosis, type of chemotherapy, risk stratification, first line treatment response, localization of the radiotherapy if applied, relapse and survival outcomes were accessed from the files and analyzed. Patients with missing data in their files, patients who left the center without completing their treatment and patients who started treatment in another center and continued in our hospital were not included in the study. **Results:** The median age was 7 years (between 2-18 years) and the male/female ratio was 3.2. Burkitt's Lymphoma (48.5%) was the most common, Lymphoblastic Lymphoma (31.7%) was the second common histopathologic subtype and the primary site of the disease was abdomen in 34 patients (56.7%). It was seen that 28 of the patients (46.6%) had extranodal involvement, CNS involvement was only in 1 patient (1.6%) and bone marrow involvement was found in 13 patients (21.6%). It was determined that

80% of the patients were in the advanced stage (Stage 3-4) and complete remission was observed in 60.1% of the patients after the first line treatment. It was observed that the overall survival rate was 80.8%, and the event-free survival rate was 75% during the 96-month follow-up. Age, gender, primary site of the tumor, presence of extranodal involvement and stage did not have a statistically significant effect on overall and event-free survival. The effect of histopathological subtype on overall survival was found to be significant and highest survival rates were observed in B cell lymphoblastic and diffuse large B cell lymphoma. It was observed that the overall and event-free survival rate was significantly lower in the group with a LDH level above 500 U/L, which was measured at the time of diagnosis ($p=0.01$ and $p=0.008$). It was seen that the treatment response and both overall and event-free survival rates were found to be significantly higher in the groups with complete and partial response after the first line treatment ($p<0.001$). The treatment-related mortality rate was found to be 45.4%, and the most common cause was febrile neutropenia/sepsis. **Conclusion:** Although childhood Non Hodgkin's Lymphomas have an aggressive nature and are detected in an advanced stage, survival results are good. It is very important to determine the risk groups to choose the appropriate intensive chemotherapy regimen and provide adequate supportive treatment for preventing treatment-related mortality and better outcomes.

<https://doi.org/10.1016/j.htct.2022.09.1268>

SOFT TISSUE SARCOMAS

PP 34

SUCCINATE DEHYDROGENASE SUBUNIT B DEFICIENT PEDIATRIC GIST

Melek Yaman Ortakoylu¹, Dilvin Celik Ates², Hale Kivrak³, Isinsu Kuzu³, Sonay Incesoy Ozdemir¹, Handan Dincaslan¹, Nurdan Tacyildiz¹, Emel Cabi Unal¹

¹ Division of Pediatric Oncology, Department of Pediatrics, Ankara University, Turkey

² Division of Pediatric Oncology, Department of Pediatrics, Inonu University, Turkey

³ Department of Medical Pathology, Ankara University, Turkey

Case report Gastrointestinal stromal tumors (GISTs) occur exceedingly rare in children and adolescents. Eighty five percent of pediatric GISTs and 15 % of adult GISTs lack oncogenic mutations in KIT and PDGFRA. The results of tyrosine kinase inhibitor therapy in GIST cases with SDH deficiency are limited and controversial. Here, we would like to present a pediatric SDH deficient GIST case treated with surgery and Imatinib Mesylate. We obtained a good response with Imatinib Mesylate.

<https://doi.org/10.1016/j.htct.2022.09.1269>

PP 35

SYNOVIAL SARCOMA ARISING IN THE RETROMOLAR TRIGONE: A RARE PRESENTATION

Asma Saleem

Karachi Institute of Radiotherapy and Nuclear Medicine

Case report A 33-year-old female presented with complaints of lesion in the left retromolar trigone. CT scan demonstrated a soft tissue mass in left buccal space extending into the left infratemporal region. Biopsy was positive for Synovial Sarcoma. She received chemotherapy followed by wide local excision. Treatment with a total of 60 Gy radiotherapy was given. Patient tolerated the treatment well and remained disease free for 4.5 years. She developed recurrence and received palliative radiation for bleeding and pain control.

<https://doi.org/10.1016/j.htct.2022.09.1270>

RARE TUMOURS AND HISTIOCYTOSIS

PP 36

ASSOCIATION OF NF-1 AND MOYAMOYA SYNDROME : CASE REPORT

Serap Karaman¹, Şifa Şahin¹,
Edibe Pembegül Yıldız²,
Hikmet Gülşah Tanyıldız¹,
Mehmet Barburoğlu³, Tutku Turgut⁴,
Yasin Yılmaz¹, Zeynep Karakaş¹,
Deniz Tuğcu¹, Ayşegül Ünüvar¹
¹ Istanbul University Faculty of Medicine,
Department of Pediatric Hematology Oncology

² Istanbul University Faculty of Medicine
Department of Pediatric Neurology Istanbul

³ Istanbul University Faculty of Medicine
Department of Radiology

⁴ Istanbul University Faculty of Medicine
Department of Medical Genetics

Introduction: Neurofibromatosis type 1 (NF-1) is the most prevalent autosomal dominant genetic disorder. NF-1 vasculopathy is a significant complication of the disease. It affects both arterial and venous blood vessels of all sizes. Also Moyamoya syndrome is a cerebral vasculopathy. It is rarely detected with NF-1 in the pediatric group. Herein, we report of a 5 year-old male with NF1 and moyamoya syndrome. **Case Report:** A 6-month-old baby boy was brought by his family with the complaint of brown spots on the body. On physical examination, cafe au lait spots on the body, subcutaneous nodule in the occipital area and hypotonicity were found. He was examined considering neurofibromatosis, one of the neurocutaneous diseases. Abdominal ultrasonography, brain MRI, echocardiography, electroencephalography were normal. There was no pathological evidence in eye examination. In genetic tests, NF1 p.Gln2217 gene was found heterozygous

positive. patient was followed up with annual brain MRI. Hamartomatous lesions in left putamen and left thalamus posterior were detected in brain MRI when the patient was two years old. There was no pathological evidence on neurological physical examination. When he was three years old thickening and enhancement of the right optic nerve was found in MRI due to possible optic glioma. Only in the left cerebellar hemisphere, two millimeter-sized hamartomatous lesions in the white matter were found to have newly developed. Both internal carotid arteries (ICA) are thinned from the supraclinoid segment. Middle cerebral artery (MCA) M1 segment on the right and anterior cerebral artery (ACA) A1 segment on the left could not be selected. Many thin collateral vascular structures were selected in these localizations and were found to be significant in terms of Moyamoya disease. Regression was detected in right optic glioma. No predisposing factor was found in the examinations of the patient for thrombosis. Acetyl salicylic acid prophylaxis was started. The patient was taken under neurosurgery follow-up for revascularization surgery. The follow-up and treatment continues. **Conclusion:** Association of NF-1 and Moyamoya syndrome is rare, but carries a potential risk of clinicoradiological progression. Closed monitoring of children with neurofibromatosis type 1 enables early diagnosis of moyamoya syndrome. Revascularization surgery may effective way to prevent progression of clinical symptoms, but long-term results require close follow-up studies.

<https://doi.org/10.1016/j.htct.2022.09.1271>

PP 37

EVALUATION AND MANAGEMENT OF THYROID NODULES AT A TERTIARY CARE PEDIATRIC CANCER CENTER IN TURKEY

Seda Şahin¹, Derya Özyörük¹,
Arzu Yazal Erdem¹, Neriman Sarı¹,
Aylin Kılınç Uğurlu², Mehmet Boyrazoğlu²,
Selma Çakmakcı¹, İnci Ergürhan İlhan¹
¹ Ankara City Hospital Pediatric Oncology
Department

² Ankara City Hospital Pediatric Endocrinology
Department

Objective: The object of this study is to search the characteristics of children and adolescents with thyroid nodules and analyze our institutional experience in the management of thyroid nodules. The complaints of these patients, physical examination findings, diagnostic features, results of radiologic researches, choice of the most appropriate modality to these patients' thyroid nodule assessment, and the management of the pathology results were revealed. **Methodology:** Patients who applied to the pediatric endocrinology or oncology outpatient clinic of Ankara City Hospital with the diagnosis of thyroid nodule were examined. All patients who has pathology result as benign, atypia of undetermined significance/follicular lesion of undetermined significance (AUS/FLUS), follicular neoplasm/ suspicious for a follicular

neoplasm (FN/SFN), suspicious for malignancy (SM), and malignant were searched. **Results:** A total of 130 patients presented with thyroid nodules. Female male ratio was 1,95:1. The youngest patient was 68 months old. At admission there was no goiter in 71.5% of the patients on physical examination. Of all patients 36% of them underwent fine needle aspiration biopsy and 8 of the 76 patients who underwent biopsy were diagnosed with papillary thyroid cancer. One patient diagnosed with follicular thyroid cancer Patients that diagnosed cancer, 4.6% of them treated with radioactive iodine. **Conclusion:** Although most pediatric thyroid nodules are benign, distinguishing benign from malignant lesions is crucial. Interdepartmental communication and competence are very important in the follow-up of patients with thyroid nodules. Because of an increased risk of cancer in the pediatric population, diagnostic and therapeutic procedures for pediatric patients need further research including multicenter studies to attain universal consensus regarding the diagnosis and management.

<https://doi.org/10.1016/j.htct.2022.09.1272>

TUMOR BIOLOGY, IMMUNOLOGY AND IMMUNOTHERAPY

PP38

TRAMETINIB EXPERIENCE IN A BRAF P.N 486 _P490DEL MUTATION POSITIVE LANGERHANS CELL HISTIOCYTOSIS

Sevim Gencil Karaaslan¹,
Gül Hatice Erkol Tuncer²,
Melek Yaman Ortakoylu²,
Sonay Incesoy Ozdemir², Handan Dincaslan²,
Nurdan Tacyildiz², Ömer Suat Fitoz³,
Koray Ceyhan⁴, Isinsu Kuzu⁵, Emel Cabi Unal²

¹ Ankara University, Department of Pediatrics,
Division of Pediatric Oncology

² Ankara University, Department of Pediatrics

³ Ankara University, Department of Pathology

⁴ Ankara University, Department of Radiology,
Division of Pediatric Radiology

⁵ Ankara University, Department of Pathology,
Division of Cytopathology

Case report In Langerhans cell histiocytosis thyroid involvement is rarely seen. Here, we would like to present a 12-year-old male patient with lung, external auditory canal skin and

lymph node involvement in diagnosis. Disease relapse occurred with thyroid involvement 19 months after remission. In molecular analysis, BRAF p.N 486_P490del was detected and he received MEK inhibitor Trametinib monotherapy. He is still in remission for 16 months.

<https://doi.org/10.1016/j.htct.2022.09.1273>

PP 39

SERUM TOTAL OXIDANT AND ANTIOXIDANT STATUS IN CHILDREN WITH CANCER

Yasin Yilmaz¹, Handan Dincaslan²,
Sonay Ozdemir², Hatice Tuncer²,
Bugra Tanrioverti², Hatice Busra Kutukcu²,
Nurdan Tacyildiz², Emel Unal²

¹ Istanbul University Istanbul Medical Faculty

Department of Pediatric Hematology and Oncology

² Ankara University Medical Faculty Department of
Pediatric Hematology and Oncology

Objective: Oxidative stress has a potential role in carcinogenesis. Antioxidant enzymes have neutralizing effect both on cancer initiation, and progression. We aimed to assess the oxidant and antioxidant levels of pediatric cancer patients and to compare the levels in healthy controls. **Methodology:** The study involved 105 pediatric cancer patients (40 undergoing chemotherapy, 65 survivors) and 40 healthy children. The serum total oxidant status (TOS) and total antioxidant status (TAS) were measured. **Results:** The TOS and oxidative stress index were lower in pediatric cancer patients compared to the levels in the controls (3.73 ± 1.35 vs. 4.21 ± 1.72 $\mu\text{mol/L}$; $p=0.08$; 0.20 ± 0.07 vs. 0.26 ± 0.10 ; $p=0.001$, respectively). The mean serum TAS level was higher in patient groups compared to the level in the control (1.87 ± 0.48 vs. 1.63 ± 0.32 mmol/L , $p=0.001$). The TAS level of children with cancer in survivors was still found to be significantly higher compared to the levels in the control group (1.85 ± 0.45 vs. 1.63 ± 0.32 mmol/L , $p=0.005$). Radiotherapy, surgery, relapsed disease, presence of metastases and receiving enteral nutritional support caused no change in the TAS/TOS level. **Conclusion:** It has been revealed for the first time that the serum total antioxidant level increased during cancer treatment and didn't normalize after cessation of therapy for a long time.

<https://doi.org/10.1016/j.htct.2022.09.1274>