



## Case Report

# Severe Relapsed Autoimmune Hemolytic Anemia after Booster with mRNA-1273 COVID-19 vaccine

Flordeluna Z. Mesina  \*

University of Santo Tomas, Faculty of Medicine and Surgery; Hospital of the Infant Jesus, Manila, Philippines

## ARTICLE INFO

## Article history:

Received 27 February 2022

Accepted 4 May 2022

Available online 30 May 2022

## Introduction

The severe acute respiratory syndrome-2 virus (SARS-Cov2) continues to be a threat worldwide, with over 415 million cases and 5 million deaths, as of the time this study was written.<sup>1</sup> All efforts to discover therapeutic, diagnostic and preventive strategies have been the priority of the medical and scientific community. By 2020, several vaccines had become available for use in different parts of the world, over 40 candidate vaccines were in human trials and over 150, in preclinical trials.<sup>2</sup> Robust data on vaccine efficacy is available in the literature and there is no question of its importance in the battle against the COVID-19. The safety of these vaccines is also well documented in clinical trials with healthy subjects, though as clinicians, we must be vigilant with patients who have pre-existing autoimmune diseases. The most common immune cytopenia reported post-vaccination was immune thrombocytopenic purpura (ITP); rarely was autoimmune hemolytic anemia (AIHA) mentioned. The AIHA is characterized by an increased destruction of red blood cells (RBCs), mediated by autoantibodies against RBC antigens. This report details the

case of a female patient with a severe relapsed AIHA after receiving the booster with mRNA-1273 vaccine.

## Case presentation

A 33-year-old female was admitted because of symptoms of severe anemia. She was apparently well until 1 day after the covid-19 booster vaccination, when she developed flu-like illness and pain at the injection site, for which she took paracetamol. After two days post-vaccination, she developed dizziness, generalized weakness and pallor. As she had a history of AIHA, which had been in remission, she immediately underwent a complete blood count. This showed severe anemia with a hemoglobin count of 52g/L; hematocrit, 0.15; WBC 5.0 segs, 65; lymphocytes, 0.24, monocytes, 0.06, and; platelets, 165,000/ul. A hematology consult was performed and an oral steroid, using prednisone 1mg/kg/day, was started. After 3 days, there was progression of symptoms and hence, the patient was advised to be hospitalized.

Upon admission, the patient appeared to be weak and was wheelchair-assisted and slow to respond, but had person,

\* Corresponding author at: University of Santo Tomas Faculty of Medicine and Surgery, Internal Medicine, Section of Hematology, Manila, Manila 1502, Philippines.

E-mail address: [plonghema@gmail.com](mailto:plonghema@gmail.com)

<https://doi.org/10.1016/j.htct.2022.05.001>

2531-1379/© 2022 Associação Brasileira de Hematologia, Hemoterapia e Terapia Celular. Published by Elsevier España, S.L.U. This is an open access article under the CC BY-NC-ND license (<http://creativecommons.org/licenses/by-nc-nd/4.0/>).

**Table 1 – Laboratory results on admission.**

Parameters	Results	Ref Range
Hemoglobin	24 g/L	120 - 170 g/L
Hematocrit	0.08%	0.35 - 0.45%
WBC	17.79	5 - 10.0 × 10 <sup>9</sup> /L
Segs	69%	0.50 - 0.70%
Lymphocytes	26%	0.20 - 0.40%
Monocytes	5%	0.00 - 0.03%
Platelet	136	150 - 450 × 10 <sup>9</sup> /L
Reticulocyte count	1150	0.5 - 1.5%
LDH	1172 U/L	< 248 U/L
Ferritin	3139.54 ng/ml	20 - 250 ng/ml
Coombs' test-Direct	Positive (IgG and C3)	
Coombs' test-Indirect	Negative	

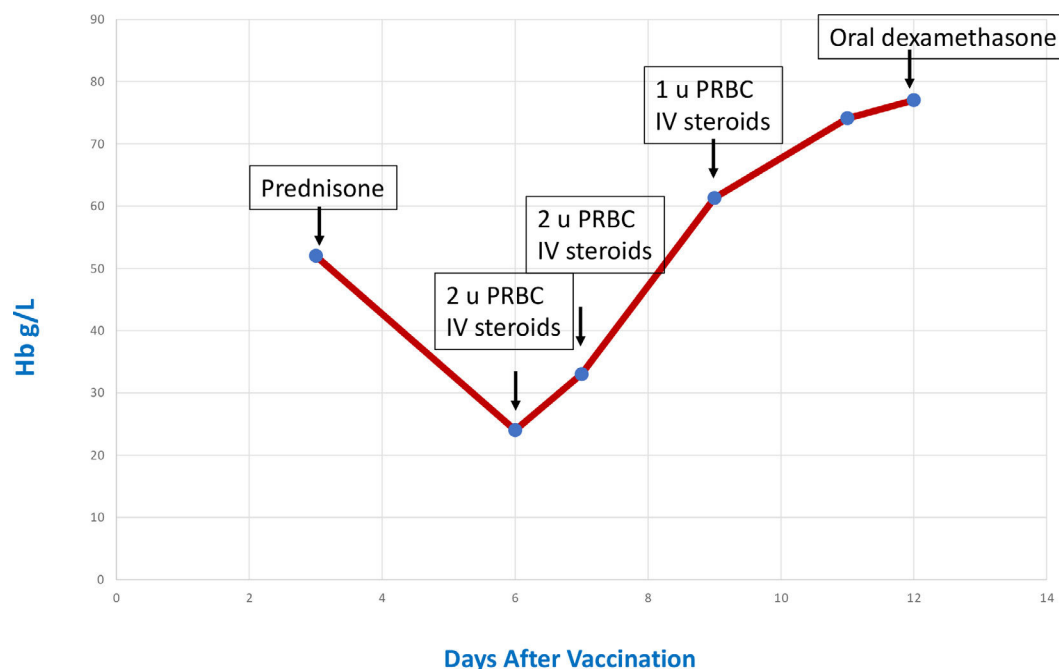
time and place orientation. Her vital signs showed a BP of 110/70; HR, 122 bpm; RR, 23, and; T, 37.0. On physical examination, the patient was pale and had sallow skin; slightly icteric sclerae; pale palpebral conjunctivae; palmar pallor, and; no hepatosplenomegaly. The laboratory exams showed severe anemia, reticulocytosis, direct Coombs' test positive (IgG and C3 positive), elevated LDH and hyperferritinemia. (Table 1) The medical history included AIHA diagnosed in 2012, with 7 episodes of hemolysis over a span of 10 years, the last of which was in late 2020 during her pregnancy and was mild, with a hemoglobin of 90 g/L, and she responded well to an oral steroid. She has been in remission thereafter. There were no illnesses in the preceding 6 months. The review of medications showed folic acid, calcium and vitamin D, with no new drugs being taken for the past 6 months. She had her primary doses of COVID-19 vaccine last June and July 2021, using the inactivated virus vaccine (Sinovac/Coronavac), which proved uneventful. Her last complete blood count (CBC) was performed during the month of her second vaccine dose, which was normal, with a hemoglobin of 132 g/L; hematocrit, 0.38;

WBC, 5.88; segs, 52; lymphocytes, 40; monocytes, 0.07, and; basophil, 0.01. Her platelet count was adequate.

The patient was started on an intravenous steroid. Packed red cells were transfused to alleviate the symptoms of anemia. There were elevations in the blood sugar while on the steroid, which were managed with insulin. The hemogram was monitored wherein a steady rise was seen during the hospitalization. (Figure 1) She was discharged stable with oral steroids.

## Discussion

Vaccination is considered the most promising approach to turn the tide in any pandemic, including COVID-19. It confers protection from viral infection by eliciting protective antibody response. Since early 2020, global attempts have been made to produce a suitable vaccine against the SARS-Cov2. Several types of vaccines were developed, namely, the inactivated virus, live attenuated, non-replicating/replicating viral vector and mRNA vaccines. Messenger RNA vaccines have emerged as front runners in the commencement of vaccination programs. They work by providing the blueprint of the pathogen's antigen. The body's ribosomes translate the mRNA into spike proteins. These are then released from the cell, allowing the host to mount an immune response.<sup>3</sup> The current evidence suggests that mRNA vaccines elicit a strong humoral response due to the production of neutralizing antibodies, coupled with a robust cellular response by inducing functional and pro-inflammatory CD4 + and CD8 + T cells and expression of Th1 cytokines.<sup>4-5</sup> Large placebo-controlled phase III trials on the mRNA-1273 reported a vaccine efficacy rate of 86.4% and 94.1% and hence, it was granted emergency use authorization (EUA) for the prevention of COVID-19.<sup>6-7</sup> These vaccine clinical trials, aside from mentioning the low incidence of local and systemic reactions (e.g. fever, chills and headache), not one has cited

**Figure 1 – Course of treatment.**

hematologic side effects. It was only during the large-scale vaccination efforts that immune thrombocytopenic purpura (ITP) and thrombocytopenia with thrombosis syndrome (TTS) for mRNA and vector-vaccine, respectively, were reported.<sup>8-10; 11-14</sup> In these reports, the exact pathogenesis was not fully determined, but autoimmunity and/or molecular mimicry were hypothesized as the possible mechanism/s.

Autoimmune hemolytic anemia (AIHA) is defined as a decompensated acquired hemolysis caused by the host's immune system acting against its own red cell antigens. It is classified as primary or secondary, depending on the presence of an underlying disease or condition promoting immune dysregulation.<sup>15</sup> There are 2 types, based on the temperature at which the antigen-antibody reaction occurs. Warm AIHA constitutes 80 to 90% of adult cases, hemolysis is mediated by IgG antibodies at 37°C while cold AIHA involves IgM antibodies with the maximal reaction at temperatures < 4°C. The rate of hemolysis and the severity of the anemia may vary from mild to severe and life-threatening. The typical laboratory features include anemia, reticulocytosis, spherocytes in blood smear, elevated LDH, indirect hyperbilirubinemia, positive Coombs' test and other specific serologic tests, depending on the type of the AIHA.<sup>16</sup> The literature has shown that both the COVID-19 infection and vaccine may trigger AIHA. Angileri *et al.*, in their correspondence to the British Journal of Hematology, found that the ANK-1 (Ankyrin-1), an RBC membrane protein shares a putative immunogenic-antigenic epitope with 100% identity to the spike glycoprotein of the SARS-CoV-2. This may lead to erythrocyte destruction through antibody cross-reactivity and molecular mimicry.<sup>17</sup> Taherifard *et al.*, in a systematic review of 58 articles, showed 58.5% (55/94 patients) developed ITP, while 23.4% (22/94 patients) had AIHA during the course of the COVID-19 infection.<sup>18</sup> This was consistent with the review by Jacobs *et al.* showing 50 patients with AIHA associated with the COVID-19 infection, the majority being the cold-type

AIHA 36% (18/50), 28% (14/50), the warm type AIHA and others, mixed and Evan's syndrome.<sup>19</sup>

Various case reports have been published regarding AIHA after COVID-19 vaccination, all of whom received the mRNA vaccine. Hemolysis was noted in the majority after the first dose, but was also seen after the second dose. The severity of the symptoms ranges from mild to severe. The diagnosis is made based on the clinical presentation, chronology of events from vaccination and confirmation with a positive direct anti-globulin test. The onset of symptoms ranged from day 2 to day 19 post-vaccination.<sup>20-24</sup> The most delayed onset reported was 3 months post-vaccination.<sup>25</sup> The standard management used in AIHA is employed in these cases. The treatment involves immunosuppression with corticosteroids, such as prednisone at 1mg/kg/day as first-line therapy. The second-line therapy includes the use of Rituximab, an anti-CD20 monoclonal antibody. And the third-line therapy includes the use of azathioprine, cyclosporine, cyclophosphamide and mycophenolate mofetil (Table 2).

In a prospective study involving 108 patients with pre-existing autoimmune cytopenia who received the COVID-19 vaccination, patients were monitored through complete blood count and LDH determination. Out of the total population, 4 patients experienced clinically significant hemoglobin reduction requiring treatment adjustment. Three of the four had received the mRNA vaccine prior to the onset of the symptoms. An increment in the steroid doses eventually improved the hemolysis.<sup>26</sup> Another retrospective study showed the possibility of relapsed autoimmune cytopenia from a pre-existing disease, which tends to be more severe and hence, should be closely monitored post-vaccination.<sup>27</sup>

This patient is unique in 2 ways; 1) she has a pre-existing autoimmune hemolytic anemia-in remission, and; 2) she completed primary Covid-19 vaccination using inactivated virus vaccine with no adverse effect. Hemolysis was only noted during her booster shot using the mRNA vaccine.

**Table 2 – Case reports of AIHA after COVID-19 vaccination.**

AuthorDate	Age/gender	Vaccine received/Dose	Onset(# of days post vaccination)	Hb level	Treatment	Outcome
Brito <i>et al.</i> May 2021	88/F	mRNA vaccine (specifics not disclosed) (Dose 2)	Day 2	4.5 g/dl	Methylprednisolone PRBC transfusion	Alive
Murdych T July 2021	84/M	Pfizer–BioNTech BNT16B2b2 mRNA vaccine (Dose 1)	Day 19	5.6 g/dl	Methylprednisolone PRBC Transfusion	Alive
Gadi <i>et al.</i> Nov 2021	41/F	Moderna SARS–CoV–2 mRNA–1273 vac- cine (Dose 1)	Day 7	7.1 g/dl	Prednisone Mycophenolate IVIG Rituximab PRBC Transfusion	Alive
Okuno <i>et al.</i> 2021	75/F	Pfizer–BioNTech BNT16B2b2 mRNA vaccine (Dose 1)	Day 14	-	Oral prednisolone	Alive
Jaydev F <i>et al.</i> Jan 2022	42/F	COVID-19 mRNA-1273 Vaccine (Dose 1)	Day 7	4.5 g/dl	Methylprednisolone 2g PRBC transfusion	Alive
Fatima Z. <i>et al.</i> Jan 2022	66/F	Moderna mRNA-1273 COVID-19 vaccine (Dose 2)	3 months	9.9 g/dl	prednisone	Alive

## Conclusion

This case showed the possibility of recurrence of the AIHA shortly after the COVID-19 vaccination. Although it cannot definitely determine any causation, we cannot exclude the possibility of the patient's mRNA vaccination as an inciting or precipitating factor. Patients with pre-existing autoimmune cytopenia should be closely monitored. A hemolytic event is responsive to steroids and other immunosuppressive agents.

## Ethical considerations

The patient's consent for publication was obtained.

## Conflicts of interest

The author declares no conflict of interest.

## REFERENCES

- COVID live - Coronavirus statistics - worldometer. Worldometers.info. Accessed February 20, 2022. <https://www.worldometers.info/coronavirus/>
- COVID-19: Vaccines Uptodate.com. Accessed February 20, 2022. <https://www.uptodate.com/contents/covid-19-vaccines>
- Van Lint S, Heirman C, Thielemans K, Breckpot K. mRNA: From a chemical blueprint for protein production to an off-the-shelf therapeutic. *Hum Vaccin Immunother*. 2013;9(2):265–74. <http://dx.doi.org/10.4161/hv.22661>.
- Sahin U, Muik A, Derhovanessian E, Vogler I, Kranz LM, Vormehr M, et al. COVID-19 vaccine BNT162b1 elicits human antibody and TH1 T cell responses. *Nature*. 2020;586(7830):594–9. <http://dx.doi.org/10.1038/s41586-020-2814-7>.
- Anand P, Stahel VP. Review the safety of Covid-19 mRNA vaccines: a review. *Patient Saf Surg*. 2021;15(1):20.. <http://dx.doi.org/10.1186/s13037-021-00291-9>.
- Baden LR, Sahly E, Essink HM, Kotloff B, Frey K, Novak S, et al. Efficacy and Safety of the mRNA- 1273 SARS-CoV-2 Vaccine. *N Engl J Med*. 2021;384(5):403–16.
- El Sahly HM, Baden LR, Essink B, Doblecki-Lewis S, Martin JM, Anderson EJ, et al. Efficacy of the mRNA-1273 SARS-CoV-2 vaccine at completion of blinded phase. *N Engl J Med*. 2021;385(19):1774–85. <http://dx.doi.org/10.1056/NEJMoa2113017>.
- Lee E-J, Cines DB, Gernsheimer T, Kessler C, Michel M, Tarantino MD, et al. Thrombocytopenia following Pfizer and Moderna SARS-CoV-2 vaccination. *Am J Hematol*. 2021;96(5):534–7. <http://dx.doi.org/10.1002/ajh.26132>.
- Helms JM, Ansteatt KT, Roberts JC, Kamatam S, Foong KS, Labayog J-MS, et al. Severe, refractory immune thrombocytopenia occurring after SARS-CoV-2 vaccine. *J Blood Med*. 2021;12:221–4. <http://dx.doi.org/10.2147/JBM.S307047>.
- Tarawneh O, Tarawneh H. Immune thrombocytopenia in a 22-year-old post Covid-19 vaccine. *Am J Hematol*. 2021;96(5):E133–4. <http://dx.doi.org/10.1002/ajh.26106>.
- Greinacher A, Thiele T, Warkentin TE, Weisser K, Kyrle P, Eichinger S. A Prothrombotic Thrombocytopenic Disorder Resembling Heparin-Induced Thrombocytopenia Following Coronavirus-19 Vaccination. *Research Square*. 2021. <http://dx.doi.org/10.21203/rs.3.rs-362354/v1>
- Schultz NH, Sørvoll IH, Michelsen AE, Munthe LA, Lund-Johansen F, Ahlen MT, et al. Thrombosis and thrombocytopenia after ChAdOx1 nCoV-19 vaccination. *N Engl J Med*. 2021;384(22):2124–30. <http://dx.doi.org/10.1056/nejmoa2104882>.
- Scully M, Singh D, Lown R, Poles A, Solomon T, Levi M, et al. Pathologic antibodies to platelet factor 4 after ChAdOx1 nCoV-19 vaccination. *N Engl J Med*. 2021;384(23):2202–11. <http://dx.doi.org/10.1056/NEJMoa2105385>.
- Akuna M, Qureshi M, Miller N. Vitt reaction associated with Johnson & Johnson covid-19 vaccine. *Chest*. 2021;160(4). A811. Available from: [https://journal.chestnet.org/article/S0012-3692\(21\)02215-7/fulltext](https://journal.chestnet.org/article/S0012-3692(21)02215-7/fulltext).
- Hill QA, Hill A, Berentsen S. Defining autoimmune hemolytic anemia: a systematic review of the terminology used for diagnosis and treatment. *Blood Adv*. 2019;3(12):1897–906. <http://dx.doi.org/10.1182/bloodadvances.2019000036>.
- Packman CH. The clinical pictures of autoimmune hemolytic anemia. *Transfus Med Hemother*. 2015;42(5):317–24. <http://dx.doi.org/10.1159/000440656>.
- Angileri F, Légaré S, Marino Gammazza A, Conway de Macario E, Macario AJL, Cappello F. Is molecular mimicry the culprit in the autoimmune haemolytic anaemia affecting patients with COVID-19? *Br J Haematol*. 2020;190(2):e92–3. <http://dx.doi.org/10.1111/bjh.16883>.
- Taherifard E, Taherifard E, Movahed H, Mousavi MR. Hematologic autoimmune disorders in the course of COVID-19: a systematic review of reported cases. *Hematology*. 2021;26(1):225–39. <http://dx.doi.org/10.1080/16078454.2021.1881225>.
- Jacobs JW, Booth GS. COVID-19 and immune-mediated RBC destruction. *Am J Clin Pathol*. 2021. <http://dx.doi.org/10.1093/ajcp/aqab210>.
- Brito S, Ferreira N, Mateus S, et al. A case of autoimmune hemolytic anemia following COVID-19 messenger ribonucleic acid vaccination. *Cureus*. 2021;13(5):e15035.
- Murdych TM. A case of severe autoimmune hemolytic anemia after a receipt of a first dose of SARS-CoV-2 vaccine. *Int J Lab Hematol*. 2022;44(1):e10–2. Available from: <https://pubmed.ncbi.nlm.nih.gov/34258873/>.
- Gadi SRV, Bruncker PAR, Al-Samkari H, Sykes DB, Saff RR, Lo J, et al. Severe autoimmune hemolytic anemia following receipt of SARS-CoV-2 mRNA vaccine. *Transfusion*. 2021;61(11):3267–71. <http://dx.doi.org/10.1111/trf.16672>.
- Okuno S, Hashimoto K, Shimizu R, Takagi E, Kajiguchi T. Development of autoimmune hemolytic anemia after BNT162b2 mRNA COVID-19 vaccination. *Rinsho Ketsueki*. 2021;62(10):1510–4. Available from: <https://pubmed.ncbi.nlm.nih.gov/34732625/>.
- Jaydev F, Kumar V, Khatri J, Shahani S, Beganovic S. A case of autoimmune hemolytic anemia after the first dose of COVID-19 mRNA-1273 vaccine with undetected pernicious anemia. *Case Rep Hematol*. 2022;2022:2036460. <http://dx.doi.org/10.1155/2022/2036460>.
- Fatima Z, Reece BRA, Moore JS, Means Jr. RT. Autoimmune hemolytic anemia after mRNA COVID vaccine. *J Investig Med High Impact Case Rep*. 2022;10:23247096211073256. Available from: <https://pubmed.ncbi.nlm.nih.gov/35045762/>.
- Fatizzo B, Giannotta JA, Cecchi N, Barcellini W. SARS-CoV-2 vaccination in patients with autoimmune cytopenias: The experience of a reference center. *AJH Wiley*.:413–5.
- Campos-Cabrera G, Torres-Salgado F-G, Campos-Cabrera S, Campos-Villagomez J-L, Campos-Cabrera V. Autoimmune cytopenias and covid-19 vaccination: Relapse and suggested treatment. *Blood*. 2021;138(Supplement 1). 4141–4141. <http://dx.doi.org/10.1182/blood-2021-145532>.